Tribute Issue

April 2021 - March 2022

Lata Mangeshkar Medical Foundation's

Deenanath Mangeshkar Hospital and Research Centre,
Pune, MS, India

We pay tribute to the music legend – Lata Mangeshkar (1929 – 2022)

Research Department, 14th Floor, Wing C, Super-speciality building, Deenanath Mangeshkar Hospital and Research Centre, Erandawane, Pune 411004, Maharashtra, India.
Phone- (020) - 4915 4456 - 61
http://www.dmhospital.org/research-aboutus

A Tribute to Lata Mangeshkar (1929-2022) from our Director – Dr D. S. Kelkar

---

Excerpts from the TOI and Pune Times Mirror – 7th of February 2022

Dr Dhananjay S. Kelkar, Director, DMHRC, Pune

Lata Didi's desire to help citizens helped her overcome the fear of hospitals

Deenanath Mangeshkar Hospital and Research Centre (DMHRC) run by the **Lata Mangeshkar** Medical Foundation is a blessing for citizens. But very few know that Lata didi was fearful of hospitals.

Dr Dhananjay Kelkar, medical director of the hospital, who has been associated with the Mangeshkar family and Didi for over 22 years, shared different aspects of the legend's life. Speaking on Didi's vision to start a hospital, he said "Deenanath Mangeshkar did not receive any proper treatment, and hence, Didi wanted to have a hospital that would be for the public. She was not interested in running it commercially".

This is when I got in touch with her. Later, I came to know that the woman who wants to have a hospital for common people has a fear of hospitals." The Bharat Ratna awardee never visited any hospital unless it was absolutely necessary. "She used to visit me at home or other places, but hardly ever at the hospital. She was always concerned about patients' feedback," he added.

Tribute contd… [The Times of India – 7th of February 2022]

A grand hospital in father's memory a long-held dream

Umesh.Isalkar
@timesgroup.com

Pune: Lata Mangeshkar burst into a rendition of *Suniyoji Araj Mhariyo* when she came to take a final round of the Deenanath Mangeshkar Hospital a day before its inauguration on November 1, 2001.

"It was evening. We were standing in the foyer just below the hospital's dome where the statue of Sant Dnyaneshwar with arms spread stands. She just broke into the song from the movie *Lekin* with the initial *taan* (rapid vocalisation) and her voice filled the surroundings with deep emotion," the hospital's director Dr Dhananjay Kelkar recalled.

Putting up a skylight dome atop the hospital's roof uniformly connecting both the sides and bringing light and ventilation to the interior was her idea. She had insisted on building the Ganesh temple on the hospital's premises. A sprawling auditorium with an elevated stage and world-class acoustics, which was then unheard of in a hospital setting, were her ideas too.

The hospital has one of its kind state-of-the-art voice clinic, where scores of singers, actors, and others have undergone therapy and treatment. Through the hospital, her Pune connection has grown from strength to strength.

"Above all, it was her vision to build a top-notch hospital without the corporate culture, accessible and affordable to all," Dr Kelkar said. He has been closely associated with Mangeshkars right since the beginning of the plan to build the hospital.

The hospital provides consultation on an out-patient-department basis to anyone who declares himself poor at just Rs 10. "We don't ask for income proofs for OPD services. It is only for admission that we seek documents like yellow or orange ration cards," Dr Kelkar said.

Her father Master Deenanath Mangeshkar died at the state-run Sassoon General Hospital in 1942. "Building a hospital in Pune in the memory of her father was her dream," he said.

The hospital has steadfastly refrained from a corporate-style functioning. "We get a lot of inquiries from people abroad about starting a medical tourism cell but that is not our vision. Didi built this hospital for people living in this country and serving them is our foremost commitment. She had complete clarity and she chose spirited and socially inclined people to run the hospital rather than give it to big corporate giants who had then approached her," he said.

Mangeshkar did the fundraising for the hospital through concerts and cricket matches.

She was actively involved in the hospital's development and expansion till 2014. "She had always been connected with the patients or citizens of Pune through the letters they sent her either to praise or criticize the hospital services. These letters were her feedback system," he said.

File photo

Cricketer Sachin Tendulkar was in the city with Lata Mangeshkar to lay the foundation of the the super-specialty wing of Deenanath Mangeshkar Hospital in Kothrud in 2010 (top); Lata Mangeshkar supervising the hospital construction work

> Never did a singer, cricketer or celebrity ask her for money for participation. When Amitabh Bachchan consented to inaugurate our cancer building, he simply sought the address and refused to accept any formalities or pleasantries, including any transport arrangement. Didi and her work commanded enormous respect among the people
>
> **Dr Dhananjay Kelkar** | DIRECTOR OF DEENANATH MANGESHKAR HOSPITAL

DEENANATH MANGESHKAR HOSPITAL AND RESEARCH CENTRE, PUNE, M.S., INDIA

PATRON, SUPPORT and DIRECTOR

Dr. Dhananjay S. Kelkar

ANNUAL REPORT 2021-22 – CONTRIBUTIONS

▪ *Dr. Vaijayanti V. Pethe*
Content and design

▪ *Dr. Shweta A. Chitharanjan*
Data compilation – Clinical Trial research program

▪ *Dr. Amrita P. Prayag*
Data compilation – In-house research program
List of publications

▪ *Mr. Raju Sawale, Department of Academics*
Data compilation – DNB thesis program
[The data was requested from the Department of Academics]

▪ *Dr. Deepchand H. Agre*
Formatting

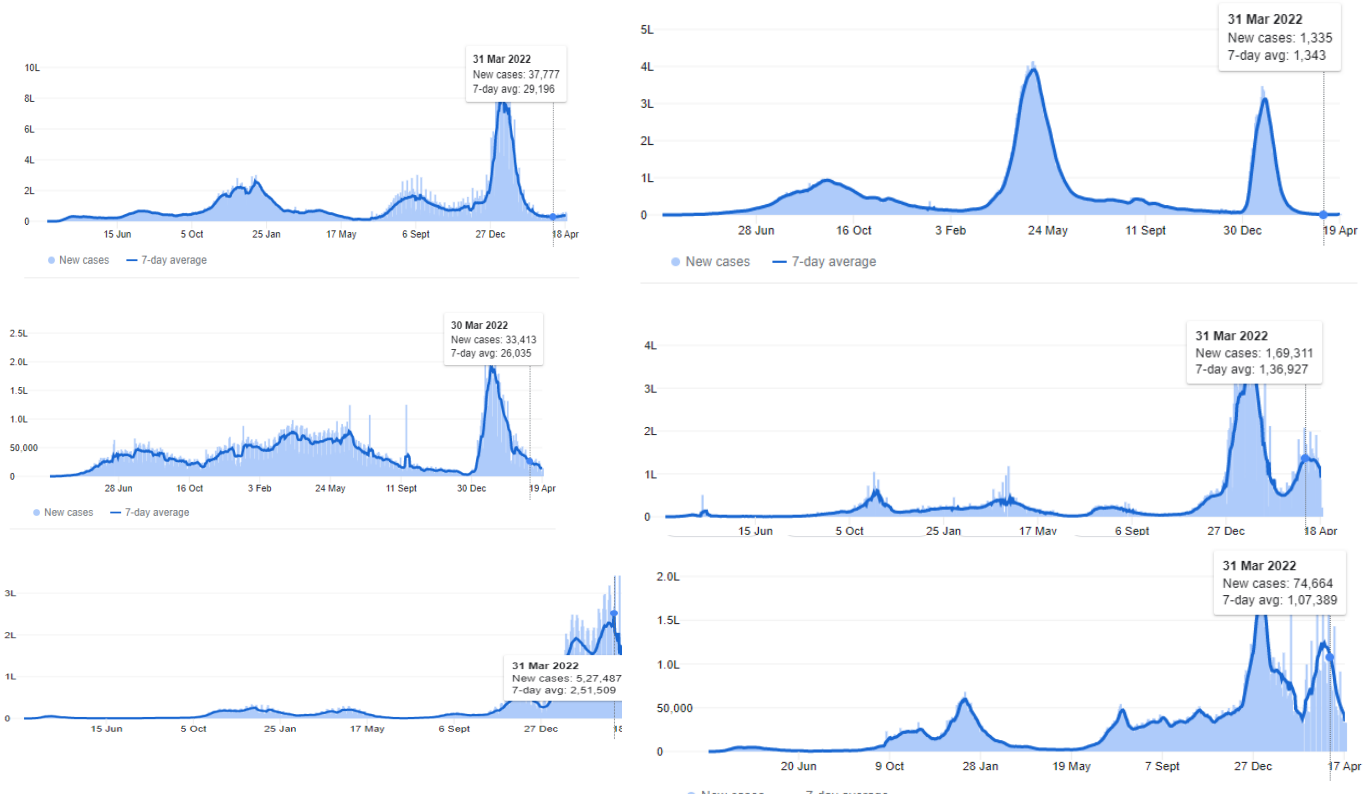

Daily new Covid cases reported – The US, India, Brazil, France, Germany and The UK (JHU-CSSE data) – *the ever-evolving Covid virus and the ever-changing pandemic.*

The unrelenting and gruesome two years of the pandemic

Beleagured and weary world pivots to living with the Covid virus and emerging variants

First and foremost, I wish to tell the readership that we have dedicated the 2021-2022 issue of annual report to the music legend – Lata Mangeshkar – as a token of our tribute to her. Lata Didi, 92, passed away in the wee hours of February 6, 2022, by contracting the Coronavirus disease and ensuing complications.

The Coronavirus disease-2019 (Covid-19), declared by WHO in March of 2020 as a global pandemic, turned out to be the most catastrophic public health crisis of our times and challenged us like never before. The turmoil unleashed by unabated Delta waves and perilous spread of Omicron across the interconnected world impacted us all. Covid-19 radically changed the work modus operandi and threw living and livelihoods into disarray. Beyond the economic and human toll, the pandemic also turned out to be a moment of reckoning for the world, with public health, healthcare research, health-disaster nexus impacts, need for global health equity and solidarity acquiring salience. Arrival of the vaccines late 2020 through early 2021 – a scientific and public health feat – provided a huge hope and vaccines were then supposed to be the light out of the pandemic. Indeed, jabs have been administered widely across the globe and have saved countless lives today. Boosters have been an additional pillar of defense. Although the Covid-era endgame remains elusive, we cannot lose the sight of the scientific progress that has been made over the past two years. Pandemic-driven new trends and norms in living and working are a reality now with multiple sectors having bounced back after their pandemic woes and lows.

Covid impacted every industry and ecosystem on this earth. The outbreak inarguably stymied the routine functioning and progress of healthcare, education and research realms. Despite the virus-linked turbulent and trying times, we remained resolute and continued to make steady contributions to practice and science. At the very outset of the pandemic, our medical Director – Dr. Dhananjay S. Kelkar weighed the real time situation and steadfastly delineated anti-contagion mandates across hospital departments and staff – all in a bid to contain the vexing infectious pathogen. Dire need was felt for instituting convictive guidelines allaying the impacts of pervasive Covid crisis situation on our integrated mission areas of patient care, education and research. Playing Covid roulette was averted at all costs in the best interest of everyone's safety, which has been the persistent need of the hour. Jabbing the entire frontline and hospital staff was considered a top priority as soon as the vaccines arrived. On the sidelines, holding a resilient approach and in earnest, our doctors and researchers revised their routines and pivoted to new clinical and research practices in ways that assured patient care while trying to keep up with research and academic commitments.

I am sharing our 2021-22 research round-up report zeroing in on our mission, vision, research and academic endeavors undertaken by our consultants and students under the (now) reality of perpetual Covid in the foreseeable future.

We all have been in the same Covid boat. We are past the crisis phase; however, the pandemic is still not fully behind us. With the ever-evolving Covid-19 virus and ever-changing behavior of the pandemic, we lost the life of certitude. Global consensus is that Covid-19 is not a temporary phenomenon. The Omicron variant has laid bare the need to live with the disease. Pandemic-linked angst, incertitude and challenges abound. Our fervent wish and hopes of eliminating Covid are now dashed. The move from pandemic phase to predictable and stable disease state appears to be accelerating; however, endemically speaking, we are not there yet. New variants will emerge – the question is not if, but when. It is hard for us to predict how the pandemic will play out in the coming months, but I believe we will use the evolving scientific knowledge about the contagion, it's successors and the disease - and continue to make informed decisions in our mission areas. The best bet is to comply with science and move on...

Our sincere thanks and acknowledgements:
We wish to earnestly thank and appreciate the efforts and time of many individuals who have contributed to this report including various clinical department heads, coordinators, clinical fellows, administrators, and of note, research consultants.

We wish the readership a safe 2022!

_____
Dr. Vaijayanti V. Pethe
Assistant Director, Research
Department of Research
Deenanath Mangeshkar Hospital and Research Center
Pune, Maharashtra, India
www.dmhospital.org

"*Leading the way to the future of personalized medicine through meticulous health research – and best practices at DMHRC"*

OUR MISSION –

Our mission is to promote scientifically sound and ethical health research in the best interest of patient care

OUR VISION –

Our vision is to advocate and deliver health research to high degree of merit and quality for the benefit of patients at large.

DEPARTMENTAL ORGANIZATION

OUR LEADERSHIP –

RESEARCH OPERATION AND PRIORITIES

Patron, support and Director [HOI] – Dr. Dhananjay S. Kelkar (2001)

Assistant Director, Research – Dr. Vaijayanti V. Pethe (2013)

In-charge, Clinical trial research program (CTR) – Dr. Shweta A. Chitharanjan (2002)

In-charge, In-house research program [IHR, Regulation] – Dr Amrita P. Prayag (2018)

OUR STAFF –

Dr Deepali Patil, (Clinical Research Coordinator, 2015)
Dr Tejashree Patole, (Clinical Research Coordinator, 2017)
Mrs Shilpa Hayatnagarkar (Clinical Research Coordinator, 2021)
Dr Deepchand Agre (IHR, Research Assistant, 2021)
Ms Sushama Batunge (Clinical Research Coordinator, 2021)
Ms Pooja Shirsat (Clinical Research Coordinator, 2022)
Mrs Varada Bivalkar (Clinical Research Coordinator, 2022)
Mr Sandeep Bhosale (Multi-Purpose Worker, 2007)

OUR INTERNS (CTR ARM) –

Ms Arti Chavan – Ms Komal Choudhari – Ms Harshada Kudale – Ms Akanksha Kale – Ms Roschelle Alex

ALUMNI - CRCS (CTR ARM) –

Dr Asmita Shembekar – Dr Smita Sawant – Dr Kirti Jalkote – Mrs Snehal Jadhav – Madhura Shirolkar – Tanuja Deshmukh – Prerna Kulkarni – Kajal Tripathi – Manisha Ghumatkar

ALUMNI - INTERNS (CTR ARM) –

Kanchan Khedkar – Shrutika Ghodekar – Kajal Tripathi – Vrushali Sawant – Mayuri Patil

TABLE OF CONTENTS

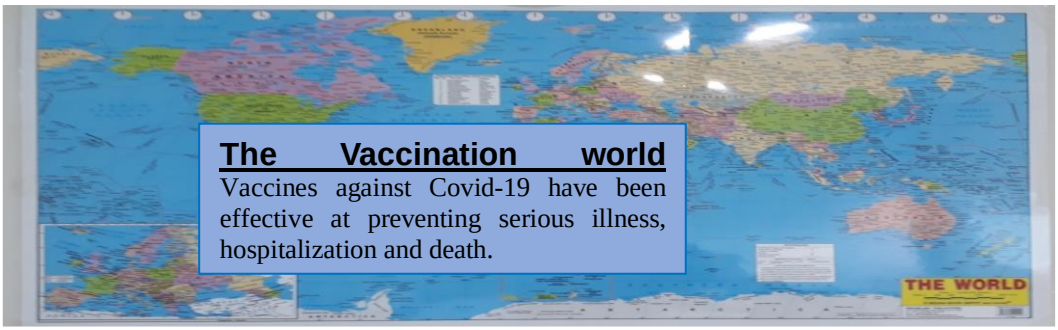

The Vaccination world

Vaccines against Covid-19 have been effective at preventing serious illness, hospitalization and death.

Please make sure to get your shots



Our Registrations / Accreditations

OUR REGISTRATIONS/ACCREDITATIONS FOR CLINICAL RESEARCH – IN-HOUSE PROGRAM, CLINICAL TRIAL RESEARCH PROGRAM – AND DNB DEGREE PROGRAM

IN-HOUSE RESEARCH PROGRAM – Biomedical and Health Research

A] We are granted SIRO registration from DSIR.

Registration validity: 1st of April 2020 through 31st of March 2023.

B] Ethics Committee (BMHR) is registered with Department of Health Research, ICMR, New Delhi

Registration validity: For 5 years starting 30th of November 2021

CLINICAL TRIAL RESEARCH PROGRAM –

A] EC registration from DCGI (CDSCO, New Delhi)

Registration validity : 1st of April 2022 through 31st of March 2027
[Re-Registration number – ECR/15/Inst/Maha/2013/RR-22]

B] The Ethics Committee of DMHRC has been granted accreditation from NABH –

Accreditation validity : 21st of January 2021 through 20th of January 2024

DNB THESIS PROGRAM –

25 Clinical departments at DMH have been accredited by National Board of Examinations, New Delhi

[Broad Speciality – 11, Super Speciality – 11, Fellowship – 03]

The list of departments is included in SOP – BMHR document.

(The data on thesis projects was requested from the Department of Academics)



Selected publications

1. Murthy R, Gote YS, Bagchi A. (February 2022)
Localized surgical debridement for the management of orbital mucormycosis.
Indian J Ophthalmol., 70(2):649-652.

Abstract:
Purpose: To describe the role of localized debridement and instillation of amphotericin B for the management of orbital mucormycosis post COVID-19 infection with a view to avoid exenteration.
Methods: The records of all patients with orbital mucormycosis post COVID-19 infection in the last 6 months from December 2020 to June 2021 were evaluated, and ten patients were identified who were successfully managed with localized debridement, that is, removing the fungal tissue and necrotic material and amphotericin B gel instillation locally. MRI scan was used to identify the area of fungal infiltration and presence of necrotic material. Early surgery in the form of transconjunctival orbitotomy was performed for disease in the infraorbital fissure area, and superior transcutaneous lid crease approach was employed for disease in the superomedial orbit or medial orbit. Most patients had lid edema, ptosis, and proptosis; this resolved with the medication. Systemic antifungals were given and the follow-up ranged from 1 to 5 months.
Results: The ptosis, proptosis, and lid edema subsided in all, except in one patient who had residual ptosis and in one who had residual ophthalmoplegia. Vision deficit did not occur in any patient. All patients were successfully discharged on oral antifungal medication.
Conclusion: Localized clearance of the fungal tissue and the necrotic material is a good option to avoid exenteration in cases of orbital mucormycosis, avoiding disfigurement and mental trauma to the patient.

2. DS Kelkar, U Kurlekar, L. Stevens, GD Wagholikar, M Slack. (February 2022)
An Early Prospective Clinical Study to Evaluate the Safety and Performance of the Versius Surgical System in Robot-Assisted Cholecystectomy
Ann Surgery doi: 10.1097/SLA.0000000000005410

Abstract:
Objective: The aim of this study was to demonstrate the ability of the Versius Surgical System to successfully and safely complete cholecystectomy. Background: The system has been developed in-line with surgeon feedback to overcome limitations of conventional laparoscopy to enhance surgeon experience and patient outcomes. Here we present results from the cholecystectomy cohort from a completed early clinical trial, which was designed to broadly align with Stage 2b of the IDEAL-D framework for surgical innovation. Methods: Procedures were performed between March 2019 and September 2020 by surgical teams consisting of a lead surgeon and operating room (OR) assistants. Male or female patients aged 18 years and over and requiring cholecystectomy were enrolled. The primary endpoint was the rate of unplanned conversion from robot-assisted surgery to conventional laparoscopic or open surgery. Adverse events (AEs) and serious AEs (SAEs) were adjudicated by video review of the surgery and patient study reports by an independent Clinical Expert Committee. Results: Overall, 134/143 (93.7%) cholecystectomies were successfully completed using the device. Of the nine (6.3%) conversions to another surgical modality, seven were deemed to be related to

the device. A total of six SAEs and three AEs occurred in eight patients (5.6%), resulting in four (2.8%) readmissions to hospital within 30 days of surgery and one death. Conclusions: This study demonstrates cholecystectomy performed using the device is as safe and effective as conventional laparoscopy and supports the implementation of the device on a wider scale, pending instrument modifications, in alignment with IDEAL-D Stage 3 (Assessment)

3. Kulkarni R, Pujari SS, Gupta D, Ojha P, Dhamne M, Bolegave V, Dhonde P, Soni A, Adwani S, et al. (February 2022)
Cerebrovascular Involvement in Mucormycosis in COVID-19 Pandemic.
J Stroke Cerebrovasc Dis., 31(2):106231.

Abstract:
Background: Many countries have seen an unprecedented rise of cases of coronavirus disease 2019 (COVID-19) associated mucormycosis (CAM). Cerebrovascular involvement in CAM has not been studied so far. We describe clinico-radiological manifestations of cerebrovascular complications observed in CAM.
Methods: In this multicentric retrospective observational study from India, patients with CAM who developed cerebrovascular involvement were studied. Their demographics, risk factors, clinical manifestations, imaging, laboratory profile and outcomes were noted.
Results: Out of 49 subjects with cerebrovascular involvement, 71.4% were males while average age was 52.9 years. Ischemic stroke was commonest (91.8%) followed by intracranial haemorrhage (6.1%) and subarachnoid haemorrhage (2%). The incidence of cerebrovascular complications in CAM was found to be 11.8% in one center. Cerebrovascular symptoms appeared a median of 8.3 days from the onset of mucormycosis. Commonest presentation of mucormycosis was rhino-orbito-cerebral syndrome in 98%. Diabetes mellitus was present in 81.7%. Forty percent developed stroke despite being on antiplatelet agent and/or heparin. Amongst subjects with ischemic strokes, location of stroke was unilateral anterior circulation (62.2%); bilateral anterior circulation (17.8%); posterior circulation (11.1%) and combined anterior and posterior circulation (8.9%). Vascular imaging revealed intracranial occlusion in 62.1%; extracranial occlusion in 3.4% and normal vessels in 34.5%. Mortality was 51% during hospital stay.
Conclusions: Cerebrovascular involvement was seen in 11.8% patients of CAM. Angio-invasive nature of the fungus, prothrombotic state created by COVID-19, and diabetes were important causative factors. Subjects with CAM should be screened for involvement of the brain as well as its vessel. Antiplatelet agents/heparin did not seem to provide complete protection from this type of stroke.

4. Suchismitha T. (February 2022)
Penetrating Keratoplasty With Minimal Endothelial Replacement: A Novel Technique for High-Risk Large-Diameter Corneal Grafting.
Cornea. 41(2):264-268.

Abstract:
Purpose: The purpose of this study was to analyze the outcome of large-diameter penetrating keratoplasty with minimal endothelial replacement (PKMER).
Methods: Two eyes (2 patients) with advanced keratoconus and central full-thickness pathology, namely, scar and failed graft, were studied. Both eyes had relatively healthy endothelium in the periphery. They were operated using the PKMER technique that involved a

large-diameter keratoplasty with retained central island of endothelium in the donor corresponding to the visual axis, whereas the peripheral Descemet membrane was removed. In effect, the peripheral endothelium and deep stroma of the recipient were preserved. Patients were followed up using anterior segment optical coherence tomography and specular microscopy postoperatively for a minimum period of 6 months in one eye and 3 years in the other.

Results: In both eyes, the central cornea maintained clarity throughout follow-up. The astigmatism reduced significantly, and the final uncorrected and best-corrected vision improved from hand motions close to the face to 6/12/n8 in one eye and 6/12/n12 in the other. Anterior segment optical coherence tomography in both eyes showed satisfactory apposition of interfaces at 1 month postkeratoplasty, and the same was maintained throughout follow-up. Both eyes withstood phacoemulsification for preexisting cataracts, which was performed in the second sitting after the PKMER. There were no complications noted except a temporary initial detachment of the peripheral interface in some quadrants in the early postoperative period.

Conclusions: PKMER may be considered as an alternative technique to large-diameter full-thickness keratoplasty. It is a relatively easier and cost-effective manual technique, which may be used as an alternative to traditional mushroom keratoplasty in selected cases.

5. Jay Bapaye , Ashish Gandhi , Rapat Pittanyanon, Pradermchai Kongkam , Amol Bapaye (March 2022)

   Video GIE, 7(3), 91-94

   Modified submucosal tunneling endoscopic resection for postcricoid esophageal subepithelial tumor

   Abstract:

   Video 1Technique of submucosal tunneling and endoscopic resection for a postcricoid subepithelial esophageal tumor. After surface marking and submucosal elevation, the mucosa was incised. The subepithelial tumor was dissected from the mucosal aspect and enucleated from the muscle layer. En bloc resection was achieved with an intact capsule. The mucosal incision was closed with endoclips.

6. Wanjarkhedkar P, Sarade G, Purandare B, Kelkar D. (Jan – Mar 2022)
   A prospective clinical study of an Ayurveda regimen in COVID 19 patients.
   J Ayurveda Integr Med., 13(1):100365.

   Abstract:
   The ancient Indian system of medicine, Ayurveda has a treatment for symptom complexes of a variety of diseases. One such combination of Ayurvedic medications has potential for use in COVID 19 infection, and hence a prospective study was conducted with this formulation as an add-on, in COVID positive patients in a dedicated COVID hospital. The objective of the study was to evaluate the additional benefit of an Ayurvedic regime in COVID positive patients on the basis of rate of clinical improvement. The Ayurvedic formulation was administered as an add-on to Standard of Care (SoC) in patients with mild to moderate symptoms, in this prospective, open-label, comparative study. Control group received SoC only. Patients receiving *Dasamoolkaduthrayam Kashaya* and *Guluchyadi Kwatham* in tablet form in addition to the SoC showed a faster recovery from breathlessness with reduced ageusia. Patients on the treatment group could be discharged earlier than those from the control group.

Addition of *Dasamoolkaduthrayam Kashaya* and *Guluchyadi Kwatham* to SoC appeared to accelerate recovery of patients hospitalized for COVID 19 infection, in terms of reduction of symptoms and duration of hospital stay.

7. Shivde, S., Kulkarni S., Date, J. and Valsangkar, R. (January 2022)
Do Changes Occur in Hemodynamic Parameters, Hemogram, Renal Function and Serum Electrolytes during Percutaneous Nephrolithotomy? Its Correlation with Irrigation Fluid and Intravenous Fluid.
Open Journal of Urology, 12, 57-68.

Abstract:
Introduction:
Percutaneous nephrolithotomy (PCNL) is a standard minimally invasive urological procedure for the treatment of large renal calculi. It is also associated with complications arising from absorption of irrigation fluid and intravenous fluid injection. We evaluated the changes occurring in vital and blood parameters during PCNL using 0.9% normal saline (NS) as an irrigation fluid.
Materials and Methods:
We prospectively studied 71 patients who underwent PCNL in our hospital between 2016 and 2018. NS (0.9%) was used as irrigation fluid in all patients. Changes in hemodynamics, hemogram, renal function tests and serum electrolytes were noted and assessed for significance using paired t-test. These changes were correlated with ASA grade, BMI, total operating time, total irrigation fluid used and total intravenous fluid used using Pearson's correlation test.
Results:
A significant fall in serum creatinine was present (1.30 ± 0.96 vs. 1.24 ± 0.93) along with a rise in eGFR (85.39 ± 24.10 vs. 90.18 ± 22.58). A significant rise in serum potassium (4.34 ± 0.45 vs. 4.5 ± 0.56) and chloride levels (104.79 ± 3.51 vs. 106.69 ± 3.14) post-operatively was noted. A significant rise in pulse rate (80.84 ± 10.13 vs. 87.76 ± 13.12) and systolic blood pressure (127.67 ± 15.90 vs. 136.88 ± 19.56) post-operatively was noted. There was no significant change noted in hemoglobin, PCV, platelets and serum sodium levels. Total operating time and irrigation fluid volume showed a positive correlation with changes in eGFR, serum chloride, post-operative pulse rate and blood pressure values. Intravenous fluids volume correlated positively with changes in serum potassium, chloride, post-operative pulse rate and blood pressure values.
Conclusion:
High amount of irrigation fluid absorption can cause early post-operative changes in patients' hemodynamics and blood indices. Overzealous hydration during PCNL with potassium containing fluids can also lead to hyperkalemia and hyperchloremic acidosis. Thus, early post-operative monitoring of serum electrolytes should be done in all patients after PCNL to prevent complications arising from dyselectrolytemia.

8. Murthy, Ramesh,; Bagchi, Aadhyaa; Gote, Yogita; Desai, Sanjay (January 2022)
Retrobulbar injection of amphotericin B using intravenous cannula for post-COVID-19 rhino-orbital mucormycosis.
Indian Journal of Ophthalmology, 70 (1) - 302-305

Abstract:

Rhino-orbital mucormycosis has seen a huge resurgence in patients post COVID-19 infection. In patients with minimal orbital disease and especially with preserved vision, retrobulbar injections of amphotericin B can be of great help in controlling the disease. Instead of giving daily injections of amphotericin B using needles every time, we used an 18-gauge intravenous (IV) cannula with injection port and suture holes to deliver the amphotericin into the orbital space for a period of 5 days. Patients were more compliant and less distressed with this method compared with being given an injection with a needle daily. We got a good response in terms of orbital disease regression with this method. In our review of the literature, we did not come across any such case of amphotericin B injection using an IV cannula. Injection of amphotericin B into the orbit using an IV cannula is a viable and easy treatment option for cases of rhino-orbital mucormycosis.

9. George, M., Solanki, A., Chavan, N., Rajendran, A., Raj, R., Mohan, S., Nemani, S., Kanvinde, S., Munirathnam, D., Rao, S., Radhakrishnan, N., Lashkari, H. P., Ghildhiyal, R. G., Manglani, M., Shanmukhaiah, C., Bhat, S., Ramesh, S., Cherian, A., Junagade, P., & Vundinti, B. R. (December 2021).
A comprehensive molecular study identified 12 complementation groups with 56 novel FANC gene variants in Indian Fanconi anemia subjects.
Human Mutation, 42(12), 1648– 1665.

Abstract:
Fanconi anemia (FA) is a rare autosomal or X-linked genetic disorder characterized by chromosomal breakages, congenital abnormalities, bone marrow failure (BMF), and cancer. There has been a discovery of 22 FANC genes known to be involved in the FA pathway. This wide number of pathway components makes molecular diagnosis challenging for FA. We present here the most comprehensive molecular diagnosis of FA subjects from India. We observed a high frequency (4.42 ± 1.5 breaks/metaphase) of chromosomal breakages in 181 FA subjects. The major clinical abnormalities observed were skin pigmentation (70.2%), short stature (46.4%), and skeletal abnormalities (43.1%), along with a few minor clinical abnormalities. The combination of Sanger sequencing and Next Generation Sequencing could molecularly characterize 164 (90.6%) FA patients and identified 12 different complementation groups [FANCA (56.10%), FANCG (16.46%), FANCL (12.80%), FANCD2 (4.88%), FANCJ (2.44%), FANCE (1.22%), FANCF (1.22%), FANCI (1.22%), FANCN (1.22%), FANCC (1.22%), FANCD1 (0.61%) and FANCB (0.61%)]. A total of 56 novel variants were identified in our cohort, including a hotspot variant: a deletion of exon 27 in the FANCA gene and a nonsense variant at c.787 C>T in the FANCG gene. Our comprehensive molecular findings can aid in the stratification of molecular investigation in the diagnosis and management of FA patients.

10. Siddiqui SS, Narkhede AM, Chaudhari HK, Ravisankar NP, Dhundi U et al (December 2021)
Clinico-demographic and Outcome Predictors in Solid Tumor Patients with Unplanned Intensive Care Unit Admissions: An Observational Study
Ind J Crit Care Med, 25(12), 1421-26

Abstract:
Objectives: Critically ill solid organ malignancy patients admitted to intensive care unit (ICU) as unplanned medical admissions behave differently from other subsets of cancer patients (hematolymphoid malignancies and cancer patients admitted for postoperative care). These patients if appropriately selected may benefit from the ICU care. There is paucity of data on

critically ill unplanned admissions of solid organ malignancies from South Asia. We analyzed data of patients with solid tumors with unplanned admissions to the ICU to determine the clinical, epidemiological characteristics, and predictors of hospital mortality in an Indian ICU. **Materials and methods:** This prospective, observational study was done in our 14-bedded mixed medical-surgical ICU from July 2014 to November 2015. We included all consecutive adult unplanned admissions with solid organ malignancies having ICU stay of >24 hours. Surgical admissions, hematolymphoid malignancies, advanced malignancy with no treatment options, and those cured of cancer >5 years were excluded. **Results:** Two hundred and thirty-five consecutive patients were included in this cohort. ICU and hospital mortalities were 36.6 and 40%, respectively. On multivariate analysis, cancer status [odds ratio (OR): 3.204; 95% confidence interval (CI): 1.271-8.078], invasive mechanical ventilation (OR: 5.940; 95% CI: 2.632-13.408), and sequential organ failure assessment (SOFA) score on the day of ICU admission (OR: 1.199; 95% CI: 1.042-1.379) were independent predictors of hospital mortality. **Conclusion:** Acute respiratory failure and septic shock are the common reasons of unplanned ICU admission for patients with solid organ malignancies. With good patient selection, more than half of such patients are likely to be discharged alive from the hospital.

11. Shilpa Kalane, Santosh Joshi (December 2021)
    A Newborn with Congenital Stridor
    Neoreviews 22(12), e854 – e858
    No abstract available

12. Kulkarni V, Potdar S, Shirol P. (December 2021)
    Rituximab in childhood pemphius vulgaris: A case report.
    Indian J Drugs Dermatol., 7 (2) :88-90

Abstract:

Pemphigus vulgaris (PV) is an autoimmune bullous disease. It has a very low incidence in childhood with very few cases reported in literatures. A 6-year-old female child had non-healing oral erosions for a month and recent appearance of genital erosions. Differential diagnoses considered were oral candidiasis, herpetic stomatitis, and PV. On investigating further, KOH mount showed Candidial hyphae and spores. Serology for herpes viruses was negative. Tzanck smear showed acantholytic cells. Obtaining biopsy from oral mucosa was difficult; hence, indirect immunofluorescence was done which showed significant titers of anti-epidermal (pemphigus) antibodies. Anti-desmoglein 1 and 3 antibodies measured by ELISA were also positive. Final diagnosis was PV. The patient was started on oral prednisolone. However, when relapsed, considering the long-term adverse effects of systemic corticosteroids on growth of the child, two infusions of rituximab, 15 days apart, were administered after clearance from a pediatrician and appropriate laboratory work up. *Outcome*: There was complete remission after 1 month of rituximab. Prednisolone was tapered off quickly and withdrawn completely. There was a persistent decline in anti-desmoglein antibodies during follow-up. No severe adverse effects were documented. The child remained in remission up to 12 months of follow-up. *Discussion*: This is a very rare case of childhood PV. Rituximab appears to be an effective therapeutic option in children with pemphigus. Further studies will help in defining protocols for use of rituximab in children.

13. Kulkarni R, Pujari S. (December 2021)
    COVID-19 associated neurological manifestations: Editorial commentary

Ann Indian Acad Neurol., 24 (6) :847-8

14. Murthy R. Bagchi A, Gote Y (Dec 2021)

Role of medial orbital wall decompression in COVID-19-associated rhino-orbital mucormycosis management

Ind J Ophthalm., 69 (12), 3795- 96

No Abstract Available

15. Kachewar, S. G., & Kachewar, S. (November 2021)

MR Imaging Spectrum of Neuro Rhino Sino Orbital Fungal Infections in patients treated for Covid.

Nepal Journal of Neuroscience, 18(4), 19–25.

Abstract:

Introduction:

Doctors across the globe need to stay abreast with daily changing complications occurring in patients already infected with COVID. Mucormycosis is one such infection affecting COVID patients and creating havoc. If detected early, dreaded complications can be prevented. Hence this study was undertaken to present and analyse the spectrum of imaging findings of fungal infection as seen in MRI images of patients who were previously treated for COVID.

Methods and Materials:

The different patterns of findings of Neuro-rhino-sino-orbital fungal infections as seen in MRI images, in 100 patients, who received standard treatment for COVID in the recent past and presented with suggestive signs and symptoms. This study proposes a new staging system [Stage 0, X, I, II, III, IV] for describing the affected region by fungal infection.

Results:

No positive MRI findings to suggest any neural tissue, orbital or sino-nasal involvement was seen in 35 % of cases. Only sino-nasal involvement was noted in 23% of cases. Sino-nasal as well as orbital involvement was seen in 21% of cases. Neuro-rhino-sino-orbital lesions were seen in 11% cases. Non fungal orbito-facial soft tissue inflammation was seen in 10% of cases.

Conclusion:

In patients who have received standard treatment for COVID and who later developed signs and symptoms of neural, orbital or sino-nasal involvement; positive imaging findings were noted in 65% cases. Fungal infections were seen more in middle aged population [40-60 years of age]. About 75 % of affected patients were known diabetics. Neural involvement was least common.

16. Ranade, A.S., Oka, G.A., Ardawatia, G. et al. (November 2021)

Lower Limb Alignment in Indian Children: A Radiographic Analysis of Coronal Plane Parameters.

JOIO (2021).

Abstract:

Objectives:
Indian children are known to have variations in the tibiofemoral angle as compared to children of other ethnicities. There is no study describing radiographic angles in coronal plane in Indian children. Our aim was to evaluate coronal plane alignment in Indian children.
Methods:
Database of radiographs between January 2011 and December 2019 was searched. Full-length standing radiographs of patients younger than 16 years with unilateral congenital or post-traumatic or post-infective deformity were included. The radiographs were measured for mechanical lateral distal femoral angle (mLDFA), medial proximal tibial angle (MPTA), tibiofemoral angle (TFA), hip–knee–ankle (HKA) angle, lateral distal tibial angle, mechanical axis deviation (MAD), and mechanical lateral proximal femoral angle.
Results:
Analysis of 221 lower limbs of 177 children is presented. There were 103 (58.2%) boys and 74 (41.8%) girls. Mean age was 8 years, 6 months (range: 2 years, 1 month to 15 years, 11 months). The mean mLDFA remained constant between 87° and 88° after the age of 5 years. The mean MPTA remained around 88° after 8 years of age. The mean MAD remained within 4 mm of the midpoint of the knee after the age of 8 years. The adult value of TFA was achieved after 8 years of age. The mLDFA, MPTA, and mLPFA are significant predictors of change in the TFA.
Conclusion:
The development of tibiofemoral angle in Indian children is slightly different than children of other ethnicities. We recommend using age-specific values for Indian children younger than 8 years of age.

17. Sumant Patil, Gayatri Bhide, Rajan Joshi and Pratibha Phasale (November 2021)

Clinical Profile of Children with SARS-CoV-2 Infection from a Tertiary Centre in Western India During the First Wave of COVID-19 Pandemic
Acta Scientific PAEDIATRICS (ISSN: 2581-883X), 4(11)

Abstract:
Background: Limited data have emerged describing the presentation and clinical characteristics of the paediatric patients with SARS CoV-2 infection. Majority of this data was from the initial part of the pandemic and mainly from China, some from Europe and USA, although none significant from the Indian sub-continent. Aim : To describe clinical profile of paediatric SARS CoV-2 infection from a tertiary centre in western India covering the first active duration of COVID -19 pandemic. Material and Methods: Retrospective observational cohort study over 6 months from 1st April 2020 to 30th September 2020. Participants:
• Children aged 0 to <18 years, admitted in hospital with COVID-19 infection.
• Positive for SARS-CoV-2 infection using RT-PCR or rapid antigen test from oropharyngeal and nasopharyngeal swabs.
Results: 148 children hospitalised with confirmed SARS CoV-2 infection were included with median age of 8.07 years (IQR 3.07 to 13.11 years) and sex ratio of 1.42 males per female. Of these 57(38.5%) were asymptomatic and 91(61.5%) were symptomatic. Fever was the commonest presenting feature in 65(43.9%), followed by cough 34(23%) and runny nose in 25(16.9%). Pediatric intensive care unit admission was needed in 9(6.1%) patients and there was one neonatal death.

Conclusion: This study confirms that the pattern of disease presentation is mild in pediatric population with a high number of asymptomatic patients and exceedingly rare mortality due to SARS-CoV-2 infection.

18. Gandhi, S., Ganesuni, D., Shenoy, S., Bhatta, S., & Dora Ghanpur, A. (November 2021).
Arytenoid Granuloma: A Single Institution Experience of Management of 62 Cases.
The Journal of Laryngology & Otology, 1-26.

Abstract:
Objectives:
This retrospective study is undertaken to assess the outcome of the medical and/or surgical management of patients presenting with clinical features of arytenoid granuloma.
Methods:
The records of 53 males and 9 females were reviewed for predisposing factors, types of treatment received and recurrence following the treatment.
Results:
Most of the patients (48/62, 77.41%) were treated conservatively with medical management and voice therapy, which resulted in a complete resolution of AG in over two-thirds of the patients treated (32/48, 66.6%). Overall, 28 patients (14 failed medical, and 14 as first-line treatment, 28/62, 45.1%) required surgery. Of these, five patients (5/28, 17.8%), showed a recurrence and were managed with revision surgery and concurrent local injection of Botox.
Conclusions:
Anti-reflux medication and voice therapy are effective first-line management. Pre and Post-surgery adjuvant treatment improves the results of surgery. Local injection of Botox was successful in the treatment of failed surgical cases.

19. Narendra S. Javadekar (October 2021)
Gut in COVID 19 – is it worth noticing
Ind Psychiatry J. 30 (Suppl 1): S267–S26

Abstract:
Although much has been talked and written about the respiratory menace that Coronavirus disease causes, a close examination reveals that gut symptoms are equally important diagnostic markers for COVID-19. Almost 53% of COVID-19 patients experience gastrointestinal (GI) symptoms. The entry of the SARS Cov-2 virus is mediated through angiotensin-converting enzyme receptors which are abundant in the GI tract. The virus also affects the GI tract through the gut lung axis. In addition to the GI tract epithelium, hepatobiliary and pancreatic systems are also affected in COVID through multiple mechanisms. GI manifestations vary from relatively benign symptoms such as nausea vomiting diarrhea to rare cases of life-threatening mesenteric vein thrombosis. The relationship of the symptoms with morbidity and mortality is not clear. Anorexia is related to inflammation, and agneusia and anosmia carry a good prognosis. Psychiatric manifestations may be more common in those with GI affection, inflammation being the common pathogenic factor. Treatment is symptomatic, and proper hygiene precautions are necessary considering the possible fecal shedding of the virus, especially during endoscopic procedures on the GI tract.

20. Rahul Kulkarni et. Al. (August 2021)
Rhino-orbito-cerebral mycosis and COVID-19: From bad to worse?

Ann Indian Acad Neurol., DOI: 10.4103/aian.aian_463_21.

Abstract:

Background: There has been an increase an alarming rise in invasive mycoses during COVID-19 pandemic, especially during the second wave.

Aims: Compare the incidence of invasive mycoses in the last three years and study the risk factors, manifestations and outcomes of mycoses in the COVID era.

Methodology: Multicentric study was conducted across 21 centres in a state of western India over 12-months. The clinico-radiological, laboratory and microbiological features, treatment and outcomes of patients were studied. We also analysed yearly incidence of rhino-orbito-cerebral mycosis.

Results: There was more than five-times rise in the incidence of invasive mycoses compared to previous two-years. Of the 122 patients analysed, mucor, aspergillus and dual infection were seen in 86.9%, 4.1%, and 7.4% respectively. Fifty-nine percent had simultaneous mycosis and COVID-19 while rest had sequential infection. Common presenting features were headache (91%), facial pain (78.7%), diplopia (66.4%) and vison loss (56.6%). Rhino-orbito-sinusitis was present in 96.7%, meningitis in 6.6%, intracranial mass lesions in 15.6% and strokes in 14.8%. A total of 91.8% patients were diabetic, while 90.2% were treated with steroids during COVID-19 treatment. Mortality was 34.4%.

Conclusion: Invasive fungal infections having high mortality and morbidity have increased burden on already overburdened healthcare system. Past illnesses, COVID-19 itself and its treatment and environmental factors seem responsible for the rise of fungal infection. Awareness and preventive strategies are the need of hours and larger studies are needed for better understanding of this deadly disease.

21. Vij N, Ranade AS, Kang P, Belthur MV. (October 2021)
Primary Bacterial Pyomyositis in Children: A Systematic Review.
J Pediatr Orthop., 41(9): e849-e854.

Abstract:

Background:

Tropical pyomyositis has had a recent increase in the United States, Europe, and other nontropical areas. The purpose of this study was to provide an accurate description of the demographics, presenting features, sites of involvement, microbiology, imaging modalities, medical and surgical management, complications, and predictors of clinical course.

Methods:

We searched PubMed, Cochrane, Web of Science Collection, Scopus, and Embase databases yielding 156 studies. Of these, 23 articles were selected for statistical analysis.

Results:

The average age at presentation was 8.4±1.9 years with males more commonly affected. Fever, painful limp, and localized pain were the most common presenting symptoms. Pelvis, lower extremity, trunk and spine, in descending order, were the most commonly affected locations. Iliopsoas, obturator musculature, and gluteus musculature were the most commonly affected muscle groups. The mean time to diagnosis was 6.6±3.05 days. Staphylococcus aureus was the most common offending organism. The mean length of hospital stay was 12.0±4.6 days. Medical management alone was successful in 40% of cases (143/361) with an average duration of 9.5±4.0 and 22.7±7.2 days of intravenous and oral antibiotics, respectively. Surgical management consisted of open drainage in 91.3% (199/218) or percutaneous drainage in 8.7% (19/218) of cases. Painful limp, fever, and larger values of

white cell count and erythrocyte sedimentation rate were associated with an increased need for surgery. Obturator and calf muscle involvement were strongly associated with multifocal involvement. There were 42 complications in 41 patients (11.3%). Methicillin-resistant S. aureus was associated with an increased risk of complications. The most common complications were osteomyelitis, septicemia, and septic arthritis.

Conclusions:

Primary pyomyositis should be considered in cases suggesting pediatric infection. Magnetic resonance imaging is the most commonly used imaging modality; however, ultrasound is useful given its accessibility and low cost. Medical management alone can be successful, but surgical treatment is often needed. The prognosis is favorable. Early diagnosis, appropriate medical management, and potential surgical drainage are required for effective treatment.

22. Solanki PK, Bhide V, Gadage V, Kulkarni V, Patki A (October 2021)
Cutaneous mastocytosis in an infant: Case report and clinicopathological correlation.
Glob J Medical Clin Case Rep 8(3): 108-111.

Abstract:

Mastocytosis is a disorder of clonal proliferation of the mast cells, which can be cutaneous or systemic. Abnormal mast cell infiltration comprising multifocal compact clusters or cohesive aggregates can affect one or more organ systems. Cutaneous mastocytosis is a relatively uncommon condition in the pediatric population. We report a case of 9 month infant presented with multiple papular and vesicular skin rashes since 6 months of age. On clinical examination Darier's sign was negative. The serum tryptase levels were within normal limits. Clinical differential diagnoses were benign cephalic histiocytosis vs cutaneous mastocytosis. Skin biopsy revealed a mononuclear cell infiltrate in the papillary dermis reaching up to the dermo-epidermal junction. Toluidine blue staining highlighted the metachromatic granules. CD117, CD30 IHC stains were positive which confirmed the diagnosis of cutaneous mastocytosis. This case is presented to highlight the histomorphology and the special stains in cases of mastocytosis.

23. Javadekar, N.S., Oka, G.A., Joshi, A.S., Vaste, P., Tamane, S. and Lawate, P.S. (October 2021)
Prevalence of irritable bowel syndrome and metabolic syndrome among young adults in an annual health check-up setting.
Journal of Gastroenterology and Hepatology Open, 5: 1148-1153.

Abstract:

Background and Aim

Some studies have found a positive association between irritable bowel syndrome (IBS) and metabolic syndrome; however, none are from India.

Methods

We conducted a cross-sectional study of 1040 adults aged between 18 and 50 years. Individuals from the annual health check-up setting were screened using anthropometry and biochemistry. Based on the results, they were identified as with and without metabolic syndrome. We excluded individuals who were already diagnosed with metabolic syndrome or those who were already on medication for diabetes mellitus or hypertension or dyslipidemia. All the participants were administered the Rome III questionnaire for the diagnosis of IBS.

Results

Metabolic syndrome was found in 307 of 1040 (29.5%) while 33 of 1040 (3.2%) had IBS. The proportion of IBS was not significantly different between participants with and without

metabolic syndrome (1.6% vs 3.8% respectively; P = 0.06). Those with IBS had significantly greater mean weight (72.4 vs 67.2 kg; P = 0.009), mean waist circumference (88.8 vs 85.2 cm; P = 0.011), mean body mass index (BMI) (26.2 vs 24.2 kg/m2; P = 0.002), and higher mean fasting glucose (96 vs 89 mg/dL; P < 0.000) respectively.

Conclusion

The prevalence of metabolic syndrome and IBS are comparable to previous literature from India. There was no association between metabolic syndrome and IBS.

24. S M Desai , A Gujarathi-Saraf, E A Agarwal (October 2021)

Imaging findings using a combined MRI/CT protocol to identify the "entire iceberg" in post-COVID-19 mucormycosis presenting clinically as only "the tip"

Clin Radiol., 76(10):784 e27-784.e33

Abstract :

Aim: To analyse combined computed tomography (CT) and magnetic resonance imaging (MRI) characteristics of invasive rhino-orbital mucormycosis (IROM) in post-COVID-19 infection patients for accurate diagnosis and delineation of the extent of involvement.

Materials and methods: A retrospective analysis was undertaken of 50 patients who developed IROM post-COVID-19 infection who underwent combined CT/MRI evaluation.

Results: The age range of the 50 affected patients was 23-73 years. Out of these, 41 were diabetic. CT/MRI showed predominant involvement of the maxillary (n=26) and ethmoid (n=19) sinuses. Extension of disease to the orbit (n=35), cavernous sinus (n=18), hard palate (n=15), skull base (n=8), and intracranial involvement (n=3) was seen. Perineural spread of the disease was analysed along all divisions of the trigeminal nerve and its branches. MRI showed T2-hypointense soft-tissue thickening with heterogeneous contrast enhancement with corresponding hyperdensities on CT diagnosing the presence of fungal elements.

Conclusion: Clinicians should be aware of the possibility of IROM post-COVID-19 infection. Conjunctive use of CT, which depicts bone destruction and other reactive bony changes along with MRI, which reveals characteristic findings of soft-tissue thickening of the involved sinuses with extension of disease to the orbits, cavernous sinus, dura, hard palate, skull base, and intracranial structures. Accurate diagnosis and early recognition of the disease and its extension with appropriate use of these techniques helps to initiate appropriate and timely treatment, which is vital to prevent a fatal outcome.

25. Waghmare S, Kharche A, Kalane S, Haridas V, Devaskar U. (September 2021)

Genesis and evolution of KIMIE: New cost-effective indigenous human breast milk pasteurizer.

Karnataka Paediatr J., 36(2) : 64-8.

Abstract:

Natural mother's breast milk is the best food for all newborns, especially preterm babies. However, if mother's milk is unavailable or donor breast milk (DBM) is inadequate, DBM is the next best choice. Human milk pasteurizers are traditionally big, costly, and require special electrical and water connections, as well as need a large volume of water that is not recycled and an ongoing supply of disposable plastic bottles. Operation of these machines necessitates specialized training. The creation of Kimie, a compact, automated, and user-friendly human breast milk pasteurizer capable of pasteurizing small volumes of DBM, is described here. This system needs no special water plumbing, recycles water, and is reasonably priced.

26. Mahapure KS, Prabhune AS, Chouvhan AV. (September 2021)
COVID-19-Associated Acute Disseminated Encephalomyelitis: A Systematic Review.
Asian J Neurosurg., 16(3):457-469.

Abstract:
Objective:
The objective of this study was to provide an overview of acute disseminating encephalomyelitis, a potential and serious complication of COVID-19.
Methods:
Three primary databases were used, PubMed, LitCovid, and WHO. The final review articles reported acute disseminated encephalomyelitis (ADEM) in COVID-19-positive patients and were full-text, peer-reviewed articles. Articles which did not have patient data such as in vitro studies and articles with unclear inference were excluded.
Results:
Out of 21 cases of ADEM, the diagnosis of severe acute respiratory syndrome-coronavirus 2 was confirmed in 18 and suspected in 3. Among the neurological symptoms, altered consciousness was most common (7/21), followed by anosmia (3), paraplegia (3/21), brain stem involvement (3/21), sphincter involvement (2/21), and quadriplegia (1/21). Raised inflammatory markers were most commonly seen in 9/17. Central nervous system imaging was abnormal in 19 cases and unavailable in 2 cases. Fifteen patients were treated with corticosteroids, 11 patients received intravenous immunoglobulin, while 3 patients received convalescent plasma. Two patients needed surgical intervention. Complications included seizures (1), acute kidney injury and septicemic shock (1), raised intracranial pressure (1), and supraventricular tachycardia secondary to hydroxychloroquine (1). One patient recovered completely and one had good recovery with mild deficits. Thirteen patients had incomplete recovery with residual neurological deficit while three patients died as the consequence of the disease.
Conclusion:
The physicians and neurosurgeons should be diligent while treating the COVID-19 patients with neurological manifestations and include ADEM as a differential diagnosis and stress on early diagnosis and treatment to reduce mortality and achieve satisfactory clinical outcome.

27. Temsah MH, Alrabiaah A, Al-Eyadhy A, Al-Sohime F, Al Huzaimi A, Alamro N et al. (September 2021)
COVID-19 Critical Care Simulations: An International Cross-Sectional Survey.
Front Public Health 9:700769.

No Abstract Available

28. Kurwale NS, Patil SB, Jagtap SA, Joshi A, Deshmukh Y, Nilegaonkar S, Bapat D, Chitnis S, Wadhwani N. (September 2021)

Surgical outcomes for medically refractory epilepsy secondary to posterior cortex ulegyria as sequelae of perinatal insults.

Epilepsy Res., 175:106703.

Abstract:

Background

To study surgical outcomes in pharmaco-resistant epilepsy associated with posterior cortex ulegyria secondary to perinatal insults.

Methods

A cohort was analysed for clinico-radiological charectaristics, surgical interventions and seizure outcomes.

Observations

A total of 38 patients underwent surgery, divided as group A - curative surgeries (n = 20) and group B - palliative surgeries (n = 18). Mean age of onset of epilepsy in group A was 5.2 ± 3.4 years against 2.7 ± 2.4 years in group B ($p < 0.01$). Electroclinical Lennox Gastaut Syndrome was encountered in 9/20 patients in group A, against all 18 patients in group B. Disabling reflex epilepsy was seen in 10 (26 %) patients.

Interictal electrophysiology localized in the posterior cortex in all patients in group A, but ictal onsets contributed in only 7/20 patients. Nine patients from group A had unilateral parieto-occipital ulegyria while bilateral in 11/20 patients, and 16/18 from group B. Group A patients underwent parieto-occipital resection (n = 10) and temporo-parieto-occipital disconnection (n = 10) while group B underwent complete corpus callosotomy (n = 18).

In group A, Engel Ia outcome was achieved in 15/20 patients (75 %) at mean follow up of 23.5 ± 7.9 months. Group B patients experienced cessation of head drops in all 18 patients, with two-third reduction in seizure frequency at 29.2± 12.4 months of mean follow up. Reflex seizures responded completely in both groups.

Conclusions

Epilepsy surgeries for posterior cortex ulegyria results in excellent seizure outcomes. Corpus callosotomy appears highly effective as a palliation for head drop as well as disabling reflex seizures in a well selected cohort.

29. Thakor B, Deshmukh Y, Jagtap SA, Kurwale N. (Sept – October 2021)

Ictal and interictal Arterial Spin Labelling (ASL) in hemimegalencephaly.

Ann Indian Acad Neurol., 24 (5):763-4

No abstract available

30. Kulkarni R, Pujari S, Gupta D. (Sep – Oct 2021)

Neurological manifestations of dengue fever.

Ann Indian Acad Neurol., 24(5) :693-702

Abstract:

Background:

Dengue is a common endemic infection in India. Neurological complications involving various parts of the neuro-axis have been reported. We report neurological complications amongst dengue patients admitted to a tertiary hospital in Western India.

Materials and Methods:

Patients admitted in a tertiary hospital in Western India with dengue infection and having neurological symptoms were included in this study. Their history, physical examination, laboratory investigations and imaging studies were obtained from the inpatient records and analysed.

Results:

Between January 2014 to December 2019, a total of 5821 patients were diagnosed with dengue. Of these, 154 (2.64%) had neurological manifestations. Encephalopathy in a setting of multisystem involvement was seen in 31.2% patients, encephalitis with focal features, abnormal imaging and/or abnormal cerebrospinal fluid (CSF) examination was seen in 15.6%, syncope in 27.3% and acute symptomatic seizure in 11.0%. Less common presentations were intracranial haemorrhage (4.5%), Guillain-Barre syndrome (GBS) (3.2%), optic neuritis (1.9%), myositis (1.3%), hypokalemic paralysis (1.3%), ischemic stroke (0.6%), posterior reversible encephalopathy syndrome (PRES) (0.6%), myoclonus (0.6%) and brachial plexopathy (0.6%).

Conclusions:

In this study of patients admitted with dengue, neurological complications due to dengue were seen in 2.64%. Encephalopathy, encephalitis and syncope were the commonest manifestations, followed by acute symptomatic seizures, intracranial haemorrhage and GBS. The entire neuroaxis can be involved in dengue infection. To the best of our knowledge, this is the largest reported study of neurological complications of dengue.

31. S. Hingmire, R. Wategaonkar, S. Hegde, M. Mekha, R. Kulkarni, A. Rajbhoj, C. Deshmukh *et. al.* (August 2021)

Outcome of COVID-19 Infection in Cancer Patients in Pune.

South Asian J Cancer, 10 (01): 23-27.

Abstract:

Introduction

We document our data on the course of the coronavirus disease 2019 (COVID-19) infection in cancer patients in an attempt to help optimize their management in India and globally.

Material and Methods

Between February 2020 and January 2021, participating oncologists from Pune (members of the Oncology Group of Pune) documented effect of COVID-19 infection in their cancer patients. Binomial logistic regression analysis as well as correlation analysis was done using Pearson Chi-square test to determine significance of clinical factors.

Results

A total of 29 oncologists from 20 hospitals contributed their data involving 147 cancer patients who developed COVID-19 infections. COVID-19 infection resulted in higher deaths (likelihood ratio of 4.4) amongst patients with hematological malignancies (12/44 = 27.2%) as compared with those with solid tumors (13/90 = 14.4%, p = 0.030). Patients with uncontrolled or progressive cancer (11/34 = 32.4%) when they got infected with COVID-19 had higher mortality as compared with patients whose cancer was under control (14/113 = 12.4%; p = 0.020). Complication of thromboembolic episodes (seen in eight patients; 5.4% cases) was associated with higher risk (25.6 times) of death (five-eighths; 62.5%) as compared with those who did not develop it (20/139;14.4%; p <0.001).

Discussion

Patients with cancer should be advised to take strict precautions to reduce the risk of being infected with COVID-19. They should also be given priority for COVID-19 vaccination. If infected with COVID-19, patients with hematological malignancy and uncontrolled cancer are

at higher risk of morbidity and mortality. When they are being treated (OPD or inpatient basis), additional precautions are necessary to ensure their exposure to potential COVID-19 virus is minimized. If they get infected with COVID-19, they should be given aggressive treatment to prevent complications, especially thromboembolic episodes. If they develop any thromboembolic complication, their risk of dying are significantly higher, and management should be modified accordingly.

32. Nilesh Mahale, Purushotham Godavarthy, Srinath Marreddy, Snehal D Gokhale, Pradip Funde, Prasad A Rajhans *et al* (Aug 2021)
Intravenous Methylene Blue as a Rescue Therapy in the Management of Refractory Hypoxia in COVID-19 ARDS Patients: A Case Series
Indian J Crit Care Med., 25(8):934-938.

Abstract:
Objectives: To describe the clinical outcomes of hypoxic coronavirus disease 2019 (COVID-19) patients treated with intravenous methylene blue (MB) in a tertiary care hospital. **Materials and methods:** We conducted a case series of 50 patients with hypoxic COVID-19 treated with intravenous MB admitted to our hospital between June 01 and September 10, 2020. Intravenous MB was administered as rescue therapy in dosage of 1 mg/kg body weight, with a maximum of five doses, to patients with high oxygen requirements (SpO_2/FiO_2 <200) apart from the standard of care after obtaining G6PD levels. Data were abstracted from multiple electronic data sources or patient charts to provide information on patient characteristics, clinical and laboratory variables and outcomes. **Results:** The median age of the patients was 53.3 (range 25-74 years) and most patients (74%) were men. About 68% of patients had pre-existing comorbidity. Median SpO_2/FiO_2 ratio progressively improved from 132.5 (predose) to 284 before the terminal event (death or discharge), ventilator-free days, and decrease in the proinflammatory biochemical parameter was significantly higher after the second dose of MB. A total of six patients out of 50 required invasive mechanical ventilation (IMV). Thirty patients were discharged with a recovery rate of 60%, while 20 patients succumbed to the illness. There was no major side effect or adverse event reported in any of the patients. **Conclusion:** MB due to its polypharmacological action against SARS-CoV-2, an inexpensive and widely available drug with minimal side effects, has a significant potential in the treatment of COVID-19.

33. Bhujel K, Bhowmick N, Gandhi S, Sharma H, Mishra D. (Aug 2021).
Primary Laryngeal Amyloidosis and CO2 Laser as the Treatment Modality.
Bengal J Of Otolaryngology and Head Neck Surgery, 29(2):119-24.

Abstract:
Introduction
Amyloidosis is brought about by intracellular and/or extracellular accumulation of insoluble abnormal amyloid fibrils that alters the normal function of the tissues. Localized laryngeal amyloidosis is a rare disease which lacks long-term follow-up studies. It is prone to recurrence; hence meticulous excision is required. We are doing this study to analyse clinical features of primary laryngeal amyloidosis, the subsites commonly found in, and the effectiveness of CO2 laser as treatment modality.
Materials and Methods
It is a retrospective study of 13 patients diagnosed as Primary Laryngeal Amyloidosis in between 2005 to 2018, where clinical features, histologic and immuno-histochemical patterns

of the patients were evaluated. Systemic amyloidosis was ruled out by the non-appearance of Bence-Jones proteins in urine and serum electrophoresis examination. Systemic workups were pursued during the follow-up. The patients were followed up 3 monthly for the first year, then 6 monthly after that, for 3 years. The last patient who underwent the surgery was in the 2018 and had just finished his 2nd follow up, while the rest have been followed up for 3 years.

Results

Hoarseness was the most common complaint in all the patients. The subsites most common for amyloid deposition were seen in the true vocal cords followed by supraglottis, anterior commissure, ventricle and the subglottis. Microscopically, the amyloid was deposited within the submucosa surrounded by lymphoplamocytic infiltration. All cases were treated with microlaryngoscopic CO2 Laser excision. With the exception of one patient, the rest had no recurrence.

Conclusion

Primary Laryngeal Amyloidosis is an uncommon benign disease that has a predisposition for recurrence. With use of CO2 laser as the primary treatment modality, the percentage of recurrence has drastically reduced. Systemic involvement should be ruled out. A frequent follow-up of the patients is desirable for early detection of recurrences. Laser is a novel treatment of laryngeal amyloidosis.

34. Phansalkar SK, Pacharne TD, Somawanshi NH, Parekh BR.(July 2021)

A randomized control study for evaluating the efficacy of individualized homoeopathic medicine as an adjuvant therapy in mild to moderate cases of Covid-19.

J Intgr Stand Homoeopathy, 4(2):40-48

Abstract:

Objectives:

Understanding the efficacy of indicated homoeopathic medicine as an adjuvant to standard treatment in improving the subjective and objective parameters in patients with mild to moderate confirmed cases of COVID-19.

Materials and methods:

Study design: A prospective randomized control trial conducted at Deenanath Mangeshkar Hospital, Erandwane, Pune, wherein Group A received standard treatment along with indicated homoeopathic medicine (experimental group) and Group B received the standard treatment and placebo (control group). Sample size: Fifty confirmed COVID positive, randomly selected patients in Groups A and B.

Results:

The indicated homoeopathic medicine as an adjuvant reduced subjective distress in a statistically significant proportion. It also reduced oxygen requirement, shortened hospital stay, promoted early recovery, and reduced worsening of the patients and shifting into the intensive care unit (ICU). By day 4 of treatment, subjective symptoms in 56% of patients in the experimental group were completely resolved, compared to 15% in the control group. The oxygen requirement on day 4 reduced by 46.2% in the experimental group, remaining unchanged in the control group. None of the patients in the experimental group needed shifting to the ICU compared to 16.7% in in the control group. The average hospital stay was 6 days in the experimental group, compared to 9 days in the control group. Conclusion:

Homoeopathic medicines played a significant role in helping to relieve the subjective and objective parameters of COVID-19.

35. Shilpa U Kalane, Asha N Gokhale, Umesh D Kalane (July 2021)
Dengue Encephalitis in a Newborn.
Indian J Pediatr., 88(7), 716

No abstract available

36. Kulkarni R, Pujari S, Palasdeokar N, Jagtap S, Jog S, Khan ZA. (Jul – Aug 2021)
COVID-19 and Acute Ischemic Stroke; An Indian Experience.
Ann Indian Acad Neurol., 24(4):632-634.
No Abstract Available

37. Rahatgaonkar VG, Deshpande AA, Oka GA. (July – September 2021)
Screening for cervical cancer in HIV-infected women: A review of literature.
Indian J Cancer 58 (3): 317-25.

Abstract:
Globally, the cervical cancer burden is huge, more so in low-resource countries. Human immunodeficiency virus (HIV) infection increases a woman's risk of human papillomavirus (HPV) infection and cervical cancer. There is a lack of opportunistic, as well as, organized cervical cancer screening structure for HIV-positive women. A large proportion of women have invasive cervical cancer as their initial acquired immune deficiency syndrome (AIDS)-defining illness. There is an especially high-incidence in countries where there are no organized cervical cancer prevention programs. Additionally, there are cultural, social, psychological, and system barriers that women living with HIV have to overcome when accessing healthcare services. We believe that educating women and healthcare providers regarding the need for screening, early detection, and treatment is as important as bringing about a systematic change in healthcare services to improve participation of HIV-positive women in screening for cervical cancer.

38. Gandhi S, Bhatta S, Bhowmick N. (July 2021)
Etiology of unilateral vocal cord paralysis: A 16-year retrospective review.
J Laryngol Voice, 11 (1) :12-16

Abstract:
Introduction: Vocal fold paralysis is a common clinical entity. Vocal fold immobility is defined as the restriction of movement of the vocal folds secondary to neuropathy or mechanical fixation. Neurogenic immobility may result from damage to the vagus and recurrent laryngeal nerve. Unilateral vocal cord paralysis (UVCP) is a highly variable clinical entity that warrants a thorough evaluation to assess the functional status of the larynx and to determine the etiology. Vocal fold paralysis is a sign of an underlying disease, not a disease in itself, and finding its etiology determines its prognosis and management options.
Aims and Objectives: To study the etiology of unilateral vocal cord paralysis in patients in a tertiary referral centre
Materials and Methods: The present study was conducted in a tertiary referral center between January 2003 and December 2019. A retrospective review of the case records of all patients diagnosed with UVCP who presented to us was carried out. A total of 435 cases who

met the inclusion criteria were considered. The etiology of UVCP was determined using history, examination and appropriately directed investigations.

Observation and Results: The most common identifiable cause of UVCP in our study was found to be surgical trauma, followed by non laryngeal malignancies.

Conclusion: Though surgical trauma has been found to be the most common etiological factor in UVCP, a large proportion of patients had idiopathic UVCP and further research as to the pathophysiology of these cases is warranted.

39. Pujari SS, Kulkarni RV, Duberkar D, Nirhale S, Nadgir D, Dhonde P, Sakale T, Shembalkar P, Meshram C. (Jul – Aug 2021)
Neurosyphilis, A True Chameleon of Neurology.
Ann Indian Acad Neurol., 24(4):566-572.

Abstract:

Background:

Neurosyphilis (NS) is a rarely encountered scenario today. Manifestations are heterogeneous, and their characteristics have changed in the antibiotic era. A differential diagnosis of NS is not commonly thought of even with relevant clinical-radiological features, as it mimics many common neurological syndromes.

Objectives:

To study the manifestations of NS in the present era and the process of diagnosis.

Method:

The data of ten patients with NS was collected and analyzed. Their background data, clinical features, investigations, the process of reaching the diagnosis, management and outcomes were recorded.

Observations and Results:

The manifestations of NS in our cohort included six patients with cognitive decline/encephalopathy and one each with meningitis with cranial nerve palsies, cerebellar ataxia, myelitis and asymptomatic NS. The presence of Argyll Robertson pupil helped to clinch diagnosis in one patient. Treponemal tests were ordered in two patients only after alternative etiologies were looked at, to begin with, whereas in six patients treponemal test was requested as a part of standard workup for dementia/ataxia.

Conclusions:

NS dementia and behavior changes are mistaken for degenerative, vascular, nutritional causes, autoimmune encephalitis or prion disease. Meningitis has similarities with infective (tubercular), granulomatous (sarcoidosis, Wegener's), collagen vascular disease and neoplastic meningitis, and myelitis simulates demyelination or nutritional myelopathy (B12 deficiency). Rarely, NS can also present with cerebellar ataxia. Contemplate NS as one of the rare causes for such syndromes, and its early treatment produces good outcomes.

40. More K, Chawla D, Murki S, Tandur B, Deorari AK, Kumar P (Jun 2021)
National Neonatology Forum (NNF) COVID-19 Registry Group. Outcomes of Neonates Born to Mothers With Coronavirus Disease 2019 (COVID-19) - National Neonatology Forum (NNF) India COVID-19 Registry.
Indian Pediatr., 58(6):525-531.

Abstract:

Background

Limited evidence exists on perinatal transmission and outcomes of severe acute respiratory syndrome coronavirus-2 (SARS-CoV-2) infection in neonates.

Objective

To describe clinical outcomes and risk factors for transmission in neonates born to mothers with perinatal SARS-CoV-2 infection.

Design

Prospective cohort of suspected and confirmed SARS-CoV-2 infected neonates entered in National Neonatology Forum (NNF) of India registry.

Subjects

Neonates born to women with SARS-CoV-2 infection within two weeks before or two days after birth and neonates with SARS-CoV-2 infection.

Outcomes

Incidence and risk factors of perinatal transmission.

Results

Among 1713 neonates, SARS-CoV-2 infection status was available for 1330 intramural and 104 extramural neonates. SARS-CoV-2 positivity was reported in 144 intramural and 39 extramural neonates. Perinatal transmission occurred in 106 (8%) and horizontal transmission in 21 (1.5%) intramural neo-nates. Neonates roomed-in with mother had higher transmission risk (RR1.16, 95% CI 1.1 to 2.4; P=0.01). No association was noted with the mode of delivery or type of feeding. The majority of neonates positive for SARS-CoV2 were asymptomatic. Intra-mural SARS-CoV-2 positive neonates were more likely to be symptomatic (RR 5, 95%CI 3.3 to 7.7; P<0.0001) and need resuscitation (RR 2, 95%CI 1.0 to 3.9; P=0.05) compared to SARS-CoV-2 negative neonates. Amongst symptomatic neonates, most morbidities were related to prematurity and perinatal events.

Conclusions

Data from a large cohort suggests perinatal transmission of SARS-CoV-2 infection and increased morbidity in infected infants.

41. Joshi DS and Joshi SD (Jun 2021).

Cataract Surgery with Systemic Diseases: Is Perioperative Management Necessary?

J Ophthalmol Adv Res., 2(2):1-10.

Abstract:

Background: Cataract Surgery is commonly done surgery in the geriatric age group. These patients may have several systemic diseases to which adequate attention must be paid during surgical planning, local anesthesia administration and in the postoperative period. This study aimed to find the actual need for any anesthetic intervention during surgery, pertaining to the patient's systemic condition.

Objectives: To assess perioperative management required for patients who have undergone cataract surgeries with respect to (w.r.t.) specific systemic comorbidities.

Methods: Hospital records of 2022 patients who had undergone cataract surgery over two years were analyzed retrospectively. 519 patients were found to have one or more systemic comorbidities and were included in this study. Data were analyzed to determine perioperative management (monitoring and interventions) required for these patients w.r.t. their systemic comorbidities.

Results: 320 patients (61.7%) were males and 199 (38.3%) were females. Various systemic diseases were observed: cardiovascular 166 (28.6%) (most common), hypertension 143 (24.7%), neurological 56 (9.1%), malignancies 39 (6.7%), renal 24 (4.1%), and respiratory 37 (6.4%). 511 (98.5%) patients did not require any preoperative interventions. 30 patients (5.8%) required intraoperative interventions like some intravenous drug injections. 2 patients (0.2%)

required the postoperative intervention of Tablet Sorbitrate for chest pain and physician's consultation. 17 (3.3%) required sedation during surgery. None required overnight hospitalization.

Conclusion: Most patients with systemic comorbidities who undergo cataract surgery under local anesthesia do not require perioperative management, with an anesthesiologist standby. Such surgeries may be safely carried out at standalone centers in a resource-limited setup with an anesthesiologist standby.

42. Bhatta, S., Sharma, D., Sharma, S. et al. (May 2021)
Smell and Taste Disturbance in COVID-19 Patients: A Prospective Multicenteric Review.
Indian J Otolaryngol Head Neck Surg., 28: 1-7

Abstract:

To study the incidence of the smell and taste disturbance in the COVID-19 patients and a follow up at 4 months to observe for the duration of resolution of these symptoms. This is a multicentric prospective study carried out in 3 different countries, from April, 2020 to January, 2021. The COVID-19 positive patients, aged between 15 and 60 years, were inquired about the presence of any smell or taste related symptoms. The same patients were followed up with the telephonic interview after 2 months and then after 4 months, respectively. The duration of resolution of the smell and taste disturbance symptoms was noted. Total of 188 COVID-19 positive patients, average age 33.1 ± 1.7 years, 54.2% males and 45.8% female were included in the study. The smell disturbance was present in 60.6% (hyposmia 36.1%, anosmia 20.2%, and parosmia 4.2%) and taste disturbance in 28.7% of patients (hypogeusia 20.2%, ageusia 6.9%, and parageusia 1.6%). There was improvement of anosmia by 97.4, hyposmia by 95.6%, parosmia by 100%, ageusia by 100%, hypogeusia 94.8%, and parageusia by 66.7%, at 4 months follow up. The present study concludes that the smell and taste disturbances are one of the main early presenting features of the COVID-19 infection. The temporary effect of the COVID-19 infection on the olfactory and gustatory pathway was also highlighted with more than 95% patients improving at 4 months of follow up.

43. Das, S., Godbole, K., Abraham, SSC, Ganesan, P., Kamdar, P., Danda, S. (May 2021)
Alazami syndrome: Report of three Indian patients with phenotypic spectrum from adolescence to adulthood.
Am J Med Genet Part A., 185 (5): 1606– 1609.

Abstract:

Alazami syndrome (ALAZS) (MIM 615071) is a rare autosomal recessive disorder characterized by short stature, dysmorphic facial features, developmental delay, and impaired intellect. It was first reported in a Saudi Arabian family in 2012. Three Indian patients affected with ALAZS, one boy aged 13 years and other two sisters in their 40s are presented. These patients had few unreported dysmorphic facial features: high arched eyebrows and dental overcrowding. No microcephaly was noted in the sisters. One of the sisters did not have short stature. The boy also presented with unilateral buphthalmos of left eye. All three of them have been identified to harbor novel variants in LARP7.

44. Ranshing S, Lavania M, Potdar V., Patwardhan S., Prayag, P., Jog S., Kelkar D., et al (May 2021)
Transmission of COVID-19 infection within a family cluster in Pune, India
Indian J Med Res., 153(5&6), 555-558.

No Abstract Available

45. Vij, Neeraj, Ranade, Ashish S., Gupte, Supriya, Oka, Gauri A., Belthur, Mohan (Apr – Jun 2021)
Tension-Sided Femoral Neck Stress Fracture in an Adolescent with Vitamin D Deficiency and Osteomalacia.
JBJS Case Connector, 11(2) - e20.00787

Abstract:
Case:
An adolescent girl presented with groin pain without any history of trauma. Imaging showed a tension-sided stress fracture of the femoral neck. Vitamin D deficiency (VDD), and raised alkaline phosphatase and parathyroid hormone levels were found. Pain relief was not achieved with nonoperative treatment. Considering the risk of fracture progression and displacement, the fracture was fixed with cannulated cancellous screws. Fracture healed without any complications.
Conclusion:
A tension-sided femoral neck stress fracture, with VDD and osteomalacia, is a rare cause of hip pain in an adolescent. Surgical fracture stabilization is necessary in addition to medical treatment.

46. Coopersmith CM, Antonelli M, Bauer SR, Deutschman CS, Evans LE, Ferrer R, Hellman J, Jog S. *et al.* (April 2021)
The Surviving Sepsis Campaign: Research Priorities for Coronavirus Disease 2019 in Critical Illness.
Crit Care Med., 49(4): 598-622

Abstract:
OBJECTIVES:
To identify research priorities in the management, pathophysiology, and host response of coronavirus disease 2019 in critically ill patients.
DESIGN:
The Surviving Sepsis Research Committee, a multi professional group of 17 international experts representing the European Society of Intensive Care Medicine and Society of Critical Care Medicine, was virtually convened during the coronavirus disease 2019 pandemic. The committee iteratively developed the recommendations and subsequent document.
METHODS:
Each committee member submitted a list of what they believed were the most important priorities for coronavirus disease 2019 research. The entire committee voted on 58 submitted questions to determine top priorities for coronavirus disease 2019 research.
RESULTS:
The Surviving Sepsis Research Committee provides 13 priorities for coronavirus disease 2019. Of these, the top six priorities were identified and include the following questions: 1) Should the approach to ventilator management differ from the standard approach in patients with acute hypoxic respiratory failure?, 2) Can the host response be modulated for therapeutic benefit?, 3) What specific cells are directly targeted by severe acute respiratory syndrome coronavirus 2, and how do these cells respond?, 4) Can early data be used to predict outcomes of coronavirus disease 2019 and, by extension, to guide therapies?, 5) What is the role of

prone positioning and noninvasive ventilation in nonventilated patients with coronavirus disease?, and 6) Which interventions are best to use for viral load modulation and when should they be given?

CONCLUSIONS:

Although knowledge of both biology and treatment has increased exponentially in the first year of the coronavirus disease 2019 pandemic, significant knowledge gaps remain. The research priorities identified represent a roadmap for investigation in coronavirus disease 2019.

47. Ichkhanian Y, Vosoughi K, Aghaie Meybodi M, Jacques J, Sethi A, Patel AA et al. (April 2021)
Comprehensive Analysis of Adverse Events Associated with Gastric Peroral Endoscopic Myotomy: An International Multicenter Study.
Surg Endosc., 35(4):1755-1764.

Abstract:

Background

Gastric peroral endoscopic myotomy (G-POEM) has emerged as an effective management approach for patients with refractory gastroparesis. This study aims to comprehensively study the safety of G-POEM and describe the predictive factors of adverse events (AEs) occurrence.

Methods

This study is a retrospective study involving 13 tertiary care centers (7 USA, 1 South America, 4 Europe, and 1 Asia). Patients who underwent G-POEM for refractory gastroparesis were included. Cases were identified by the occurrence of AEs. For each case, two controls were randomly selected and matched for age (± 10 years), gender, and etiology of gastroparesis.

Results

A total of 216 patients underwent G-POEM for gastroparesis. Overall, 31 (14%) AEs were encountered [mild 24 (77%), moderate 5 (16%), and severe 2 (6%)] during the duration of the study. The most common AE was abdominal pain (n = 16), followed by mucosotomy (n = 5) and capnoperitoneum (n = 4), and AEs were most commonly identified within the first 48-h post-procedure 18 (58%). The risk of adverse event occurrence was significantly higher for endoscopists with experience of < 20 G-POEM procedures (OR 3.03 [1.03–8.94], $p < 0.05$).

Conclusion

G-POEM seems to be a safe intervention for refractory gastroparesis. AEs are most commonly mild and managed conservatively. Longitudinal mucosal incision, use of hook knife, use of clips for mucosal closure and endoscopist's experience with > 20 G-POEM procedures is significantly associated with decreased incidence of AEs.

48. Sahasrabudhe PB, Pradhan MD, Panse N, Jagtap R. (April 2021)
Post-CABG Deep Sternal Wound Infection: A Retrospective Comparative Analysis of Early versus Late Referral to a Plastic Surgery Unit in a Tertiary Care Center.
Indian J Plast Surg. 54(2):157-162.

Abstract:

Background

Deep sternal wound infections (DSWI) following median sternotomy are initially treated by the cardiothoracic surgeons and are referred to a plastic surgical unit late in the course of time.

Methods

This is a retrospective review done in a tertiary care teaching institute from January 2005 to June 2018 and the data of 72 patients who had DSWI out of 4,214 patients who underwent

median sternotomy for coronary artery bypass grafting (CABG) was collected with respect to the duration between CABG and presentation of DSWI as well as time of referral to a plastic surgery unit. We defined early referral as < or equal to 15 days from presentation and late referral as > 15 days. Both groups were compared with respect to multiple parameters as well as early and late postoperative course, postoperative complications, and mortality.

Results

The early group had 33 patients, while the late group had 39 patients. The number of procedures done by the cardiothoracic team before referral to the plastic surgery unit is significant ($p = 0.002$). The average duration from the presentation of DSWI to definitive surgery was found to be 16.58 days in the early group and 89.36 days in the late group. The rest of the variables that were compared in both the groups did not have significant differences.

Conclusion

There is no statistical difference between early and late referral to plastic surgery in terms of mortality and morbidity. Yet, early referrals could lead to highly significant reduction in total duration of hospital stay, wound healing, and costs. Early referral of post-CABG DSWIs to Plastic surgeons by the cardiothoracic surgeons is highly recommended.

49. Date JA, Nathani AS, Shivde SR, Kulkarni CR. (Apr – Jun 2021)
Combined ureterocalicostomy with buccal mucosa graft ureteroplasty in complex upper ureteral stricture: A rare case of reconstruction.
Urology Annals, 13 (2):186-9
Case report

Abstract:

The treatment of a major and complex ureteric stricture requires the use of a bowel interposition or autotransplantation of the kidney, which is a major undertaking and remains the traditional option. Buccal mucosa is an established tissue for urethral reconstruction and can be used safely for the repair of narrowing of the ureter. This technique has been well documented in the literature; however, a combined ureterocalicostomy with buccal mucosa graft ureteroplasty has not yet been reported in literature. We report the case of a 59-year-old female who was diabetic and hypertensive presented with a long-length, complex upper ureteric stricture with recurrent pyelonephritis. A long stricture in the upper ureter measuring approximately 8 cm was successfully repaired by free buccal mucosal onlay patch graft over a double J stent with ureterocalicostomy. This technique can be used in salvaging kidneys with complex ureteric strictures along with fibrotic pelvis.

50. S Kalane et al. (April 2021)
Early onset SARS-CoV-2 pneumonia in a preterm neonate.
Int J Ped & Neo Heal. 5 (4), 33-36
Case report



Training, CMEs and educational events

Topic	Date	Speaker
Thesis Protocol Writing : Training to the new DNB trainees on the details of how a DNB Thesis Protocol is written in accordance with the guidelines by the National Board of Examinations.	24 February 2022	Dr Amrita P. Prayag (In-charge, IHR regulation, RD)
Clinical research under the Covid cloud: Training-cum-seminar program on guidelines and rules in research Organizers – Dr. Pethe V. (DMHRC, Pune) and Dr. Ghooi R. (ERI, Pune)	14 November 2021	Patron, support and Director – Dr. Dhananjay S. Kelkar Program moderator – Dr. Amrita P. Prayag Speakers – (Topic) – 1. Dr Vaijayanti V. Pethe (Preamble) 2. Dr. Ravindra Ghooi, ERI, Pune (New Drugs and CT Rules, 2019) 3. Dr. Aditi Apte, KEM Hospital and Research Center, Pune (ICMR guidelines, 2017 and 2020) 4. Dr. Padmaj Kulkarni, DMHRC, Pune (ICH-GCP guidelines with clinical scenarios- R1 and R2) Program logistics, registration and coordination – - Dr. Shweta A. Chitharanjan - RD_CRC team (Dr Deepali, Dr Tejashree, Dr Smita, Ms Prerna, Mrs Tanuja, Ms Susmita and Mrs Shilpa)



In-house research program

IN-HOUSE RESEARCH AT-A-GLANCE

NUMBER OF PROJECTS REVIEWED IN DIFFERENT THERAPEUTIC AREAS [403 TO 455; N = 53]

COVID PIVOTED RESEARCH

S. NO. DEPARTMENT	NUMBER OF PROJECTS REVIEWED [N = 15]
1. CCM/ICU	2
2. NEPHROLOGY	1
3. HOMEOPATHY	1
4. SIMULATION	1
5. ORTHOPEDICS	2
6. EPILEPSY	1
7. RADIODIAGNOSIS	2
8. MEDICAL ONCOLOGY	1
9. INFECTIOUS DISEASES	2
10. PEDIATRICS	1
11. MEDICINE	1

NON-COVID RESEARCH

S. NO. DEPARTMENT	NUMBER OF PROJECTS REVIEWED [N = 38]
1. ENDOCRINOLOGY	1
2. HOMEOPATHY	1
3. AYURVEDA	1
4. ORTHOPEDICS	4
6. EPILEPSY	8
7. MEDICAL ONCOLOGY	1
8. INFECTIOUS DISEASES	2
9. PEDIATRICS	2
10. CARDIAC ANESTHESIA	1
11. IVF/ANDROLOGY	4
12. VOICE CLINIC	3
13. OPHTHALMOLOGY	1
14. NEUROLOGY	4
15. GASTROENTEROLOGY	3
16. OB/GYN	1
17. CLINICAL BIOCHEMISTRY	1

IN-HOUSE RESEARCH AT DMHRC – PROJECTS SUBMITTED FOR REVIEW BY SAC/IEC – [N = 53; IHR 403 TO 455]

COVID PIVOTED RESEARCH

[N = 15]

Sr. No.	DMH project code	PI	Title of the project
1.	IHR_2021_Apr_SK_404	Dr. Sarang Naresh Kshirsagar	A Retrospective Observational comparative Study of Hypoxic Covid-19 Patients Treated with Remdesivir in a Tertiary Care Hospital
2.	IHR_2021_Apr_AM_406	Dr. Atul Mulay	Predicting severity of disease progression in Covid patients using electronic health data (Rejected study)
3.	IHR_2021_May_VU_407	Dr. Vaibhavi Upadhye	Covid Pandemic Preparedness of A Tertiary Hospital Using Simulation In a Resource Limited Setting.
4.	IHR_2021_May_SP_409	Dr. Shirish Phalsankar	Usefulness of different groups of Homoeopathic medicines in an Adjuvant therapy in moderate Covid-19 cases in Second Wave.
5.	IHR_2021_May_AB_412	Dr. Ashish Babhulkar	Prospective study of Vaccine associated Dysfunction of Shoulder (VADS): specifically related to Covid-19 vaccine.
6.	IHR_2021_June_NK_418	Dr. Nilesh Kurwale	Stellate ganglion block (SGB) for Covid-19 Acute Respiratory Distress Syndrome (ARDS)
7.	IHR_2021_June_AB_419	Dr. Ashish Babhulkar	A prospective analysis of upper limb neuropathy following Covid-19 infection
.8	IHR_2021_Jul_ND_ 421	Dr. Nivedita Divekar	Retrospective observational study of Covid-19 patients diagnosed with pneumomediastinum on CT scan.
.9	IHR_2021_Jul_ RC_422	Dr. Ritika Chamadia,	Two sides of the same coin/ Covid: Thrombosis and hemorrhage in the abdomen.

Sr. No.	DMH project code	PI	Title of the project
10	IHR_2021_Sep_PK_429	Dr. Padmaj Kulkarni	Deciphering Role of immunogenic factors in tumour recurrence NSCLC patients with and without COVID-19 infection using integrative genomic approach (Rejected study)
11	IHR_2021_Oct_SP_433	Dr. Sumant Patil	A Retrospective analysis of MIS-C associated illnesses during the Covid-19 pandemic in pediatric population in a span of 18 months at a tertiary centre in Western India
12	IHR_2021_Oct_PP_434	Dr. Parikshit Prayag	FISF Multicenter Mucormycosis In Covid (Mucovi-2) Study (Withdrawn by PI)
13	IHR_2021_Nov_PP_435	Dr. Parikshit Prayag	Clinical and immunological profiling of post-COVID syndrome among patients attending a tertiary care centre in Pune, Maharashtra
14	IHR_2021_Dec_PV_442	Dr. Parag Vaste	Outcome of severe Covid-19 pneumonia in Vaccinated and non-vaccinated cohorts.
15	IHR_2022_Mar_NM_454	Dr Nilesh Mahale	To determine the incidence of VAP associated with active and passive humidification in SARS-COV-2 patients.

NON- COVID RESEARCH – [N = 38] –

Sr. No.	DMH project code	PI	Title of the project
1.	IHR_2021_Apr_NK_403	Dr. Nilesh Kurwale	EEG source localization assisted to aid in surgical planning of epilepsy surgeries and other brain disorders
2.	IHR_2021_Apr_SP_405	Dr. Parikshit Prayag	Retrospective Observational study - Prevalence of Candida Auris Candidemia in Crtitical care at Tertiary Care Center
3.	IHR_2021_May_NJ_408	Dr. Nilesh Juvekar	Use of video laryngoscope to reduce complications of trans esophageal echocardiography probe insertion: A multicenter randomized study.
4.	IHR_2021_May_SP_410	Dr. Sandeep Patil	Antiepileptic drug withdrawal following epilepsy surgery: A randomized controlled study
5.	IHR_2021_May_AS_411	Dr. Anand Shinde	Use of Andrology Lab parameters for predicting success of Homologous IUI – A Retrospective study of consecutive 1319 cases.
6.	IHR_2021_May_SJ_413	Dr. Sujit Jagtap	A study of seizures in cerebral venous sinus thrombosis
7.	IHR_2021_May_AR_414	Dr. Ashish Ranade	A study of variation among pediatric orthopaedic surgeons while interpreting an elbow arthrogram in children
8.	IHR_2021_June_SJ_415	Dr. Sujit Jagtap	Neonatal hypoglycaemic brain injury (NHBI): prospective study and long-term outcome.

Sr. No.	DMH project code	PI	Title of the project
9.	IHR_2021_June_SJ_416	Dr. Sujit Jagtap	To study Clinical profile, radiological features, treatment and outcome of Rasmussen's encephalitis
10.	IHR_2021_June_SJ_417	Dr. Sujit Jagtap	Quantitative study of Peripartum and postpartum Depression, Anxiety and quality of life in women with epilepsy
11.	IHR_2021_June_AS_420	Dr. Anand Shinde	Novel Relationship study of Big Halo and DFI among men with history of BOH versus history of infertility :A Retrospective study of cases undergoing DFI
12.	IHR_2021_July_SG_423	Dr. Sachin Gandhi	Granular Cell Tumour of Supraglttis: A Case Report
13.	IHR_2021_July_SG_424	Dr. Sachin Gandhi	Localised Laryngeal Amyloidosis: A Case report
14.	IHR_July_2021_SG_425	Dr. Sachin Gandhi	Vallecular Cyst: 10 Years Experience and Review of the Literature
15.	IHR_Aug_2021_SD_426	Dr. Sameer Datar	A case series of a technique Modified for Ocular surface reconstruction 'Modified - Simple Limbal Epithelial Transplant technique (M-SLET)
16.	IHR_Aug_2021_SP_427	Dr. Shireesh Phansalkar	Efficacy of indicated homoeopathic medicine as an adjuvant therapy in Hypothyroidism Cases
17.	IHR_Aug_2021_RK_428	Dr. Rahul Kulkarni	To Assess Personality Dimension and Depression in Post Stroke patients
18.	IHR_Sept_2021_RK_430	Dr. Rahul Kulkarni	Quality monitoring registry for Analysis of stroke care for hospital.

Sr. No.	DMH project code	PI	Title of the project
19.	IHR_2021_Oct_RK_431	Dr. Rahul Kulkarni	Clinical Outcomes in Myasthenia Gravis: a multicenter study
20.	IHR_2021_Oct_SK_432	Dr. Shilpa Kalane	Respiratory Syncytial Virus Infection in NICU Graduates
21.	IHR_2021_Nov_AB_436	Dr. Amol Bapaye	Outcomes of Per oral endoscopic myotomy (POEM) in patients with Epiphrenic diverticulum – An international multicenter study
22.	IHR_2021_Nov_AB_437	Dr. Amol Bapaye	Incidence and Risk Factors for the Recurrence of Ampullary Polyps after Endoscopic Papillectomy: A Multicenter, Retrospective Study
23.	IHR_2021_Nov_SC_438	Dr. Sonal V Chitnis	Neurocognitive profile in LGI1 pre and post Immunotherapy and clinical correlation
24.	IHR_2021_Nov_AB_439	Dr. Ashish S. Babhulkar	A prospective, single-arm, multi-centre, post market clinical follow-up study to evaluate the safety and performance of Bio absorbable Ligament Anchor in Shoulder Rotator Cuff Repair
25.	IHR_2021_Dec_PP_440	Dr. Parikshit Prayag	Analysis of serum levels of posaconazole tablet in the Indian population
26.	IHR_2021_Dec_VD_441	Dr. Vaishali Deshmukh	Audit of cases of Primary Hyperparathyroidism Cases presenting to Tertiary Care Centre in Pune, India.
27.	IHR_2021_Dec_NK_443	Dr. Nilesh Kurwale	Development of Diffuse Reflectance Spectroscopy (DRS) in defining epileptogenic zone during epilepsy surgeries

Sr. No.	DMH project code	PI	Title of the project
28.	IHR_2021_Dec_NK_444	Dr. Nilesh Kurwale	To test the clinical utility of the inhouse developed neuro navigation system and compare it with commercially available system.
29.	IHR_2021_Dec_AS_445	Dr. Anand Shindhe	Cost saving by correlating Dark purple stained sperms in Toluidine Blue with DNA Fragmentation Index by Commercial SCD (Sperm Chromatin Dispersion Assay) kit.
30.	IHR_2021_Dec_SP_446	Dr. Sachin Palnitkar	Efficacy of combination of Midodrine with weekly albumin infusion Versus standard medical therapy in Decompensated liver cirrhosis – a Multicentric study
31.	IHR_2021_Dec_CD_447	Dr. Chetan Deshmukh	Study of Dietary problems and prevalent practices in patients on cytotoxic chemotherapy
32.	IHR_2022_Jan_SN_448	Dr. Sadanand Naik	Daily milk intake by vegetarian pregnant women improves the vitamin B12 status of mothers and offspring as compared to synthetic pills
33.	IHR_2022_Jan_KM_449	Dr. Keyur Mahajan	Evaluation of clinical spectrum, antibiotic sensitivity and management practices in the pediatric age group (0 to 18 years) with Extended Spectrum Beta Lactamase (ESBL) producing *E. Coli* associated urinary tract infection in tertiary care hospital in India.

Sr. No.	DMH project code	PI	Title of the project
34.	IHR_2022_Jan_PW_450	Dr. Pankaj Wanjarkhedkar	Role of Ayurveda regimen for Chemotherapy induced Nausea and Vomiting (CINV) prophylaxis in Breast Cancer
35.	IHR_2022_Feb_MK_451	Dr. Mahesh Kulkarni	Prosthetic joint infections - An analysis of organisms and their management conundrum in a tertiary care centre in India
36.	IHR_2022_Feb_AK_452	Dr. Aparna Kulkarni	Pregnancy outcome in foetuses with hypoplastic/absent nasal bone
37.	IHR_2022_Feb_YP_453	Dr. Yogesh Panchwagh	Giant cell tumor of bone- A retrospective study of 232 patients.
38.	IHR_2022_Mar_AS_455	Dr Anand Shinde	Retrospective Observational study of Quality of Embryos on Day 3, in ICSI cycles with severe Male factor infertility



Clinical trial research program

Vaccine research across the century – 1921-2021

Covid-19 vaccines 2020 through 2021

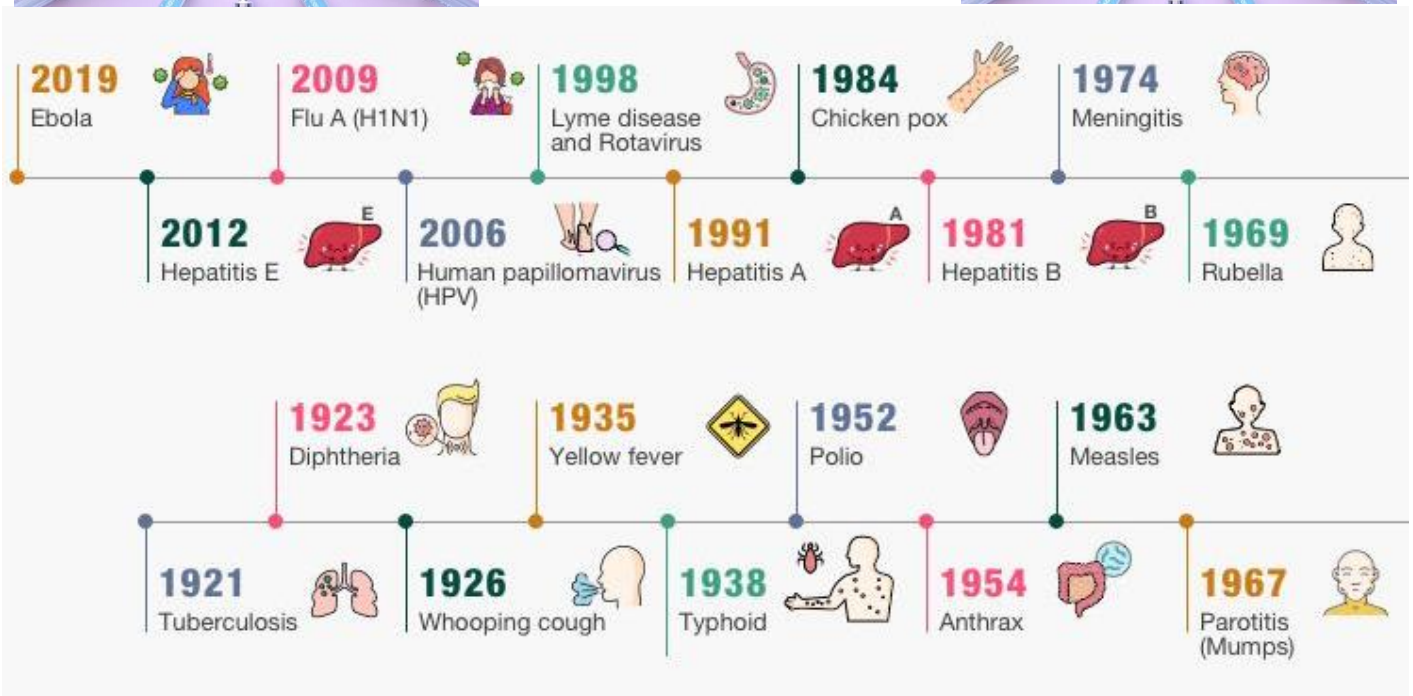

Vaccines against Covid-19 have been effective at preventing serious illness, hospitalization and death. Please make sure to get your shots.

CLINICAL TRIAL RESEARCH PROGRM AT DMHRC – PROJECTS REVIEWED BY SAC/IEC AND THEIR STATUS

A] TOTAL NUMBER OF PROJECTS REVIEWED – [N = 20]

[CT_2021_Apr_SP_645 to CT_2022_Mar_CD_665]

PROJECT STATUS	NUMBER OF PROJECTS [N= 20]
Ongoing	03
Pending	15
Rejected/ Terminated	02

Pending status – The projects have not been given final approval in view of lack of either administrative and/or regulatory documents in the context of clinical trials. Some of the documents and items include – Final CTA, EC review fees, final ICFs, CTRI notification, DCGI submission/ approval notification.

B] STATUS OF CLINICAL TRIAL STUDIES AND THEIR THERAPEUTIC AREAS – UPDATED AS OF MARCH 2022

Ongoing and inactive projects –

Total number of studies N=	51
Studies having ongoing patient activities N=	38
Inactive studies – formal close-out from sponsor awaited N=	13

C] THERAPEUTIC AREAS OF ONGOING PROJECTS – [N= 38]

THERAPEUTIC AREA	NUMBER OF ONGOING TRIALS [N= 38]
Infectious Diseases	1
Endocrinology	3
Dermatology	1
Cardiology	1
Critical Care Medicine	2
Medicine	1
Psychiatry	1
Neurology	9
Oncology	16
Rheumatology	3

D] CLOSED-OUT PROJECTS AND THEIR THERAPEUTIC AREAS [N=13]

THERAPEUTIC AREA	NUMBER OF PROTOCOLS [N=13]
Intensive Care	1
Endocrinology	1
Neurology	3
Oncology	3
Ophthalmology	2
Surgery	3



DNB thesis program

DNB THESIS PROGRAM AT DMHRC – PROJECTS ACCEPTED BY NBE
[Data Was Requested From The Department Of Academics]

Sr. No.	Name Of Principal Investigator	Name Of Guide / Supervisor	Specialty / Department	Title Of Thesis Protocol
1	Dr. Poorvi Tiwari	Dr. Sumeet Pitkar	Paediatrics	"A comparative study to assess effect of intravenous Levetiracetam (LVT) and Phenobarbitone (PHB) on cessation of neonatal seizures."
2	Dr. Sapra Keyur Piyush	Dr. Amit R.Walimbe	General Medicine	"To study the correlation between C-Reactive protein and D – dimer in patients of Pulmonary Embolism in COVID-19 infection"
3	Dr. Thumar Nikhil Vasantbhai	Dr. Arti Rajhans	Paediatrics	"Comparison of accuracy and feasibility in measurement of heart rate by electrocardiography and pulse oximetry in newborn in delivery room."
4	Dr. Aadhyaa Bagchi	Dr. Roopali Nerlikar	Ophthalmology	Retroprospective observational study to evaluate the development of refractive errors in preterm infants based on the degree of prematurity."
5	Dr. Asha Gangwar	Dr. Anuradha Wakankar	Obstetrics and Gynaecology	To study the umbilical cord coiling index and its relation to perinatal outcome
6	Dr. Maruf Altaf Khatri	Dr Parasnis Amit	General Surgery	A Prospective Observational study to compare Laparoscopic Umbilical and Paraumbilical Hernia Repair with Open Umbilical and Paraumbilical hernia Repair."
7	Dr Avinash Sapre	Dr. Kanitkar Shridhar Vinayak	General Surgery	"Prospective Observational study to determine Predictive value of Modified Alvarado score to diagnose acute appendicitis and severity of acute appendicitis."
8	Dr. Karthic Venkatakrishna	Dr. Milind Modak	Orthopaedic Surgery	"Comparison of CT and MRI in patient with tibial plateau fracture to predict associated soft tissue injury."
9	Dr. Rhea Jagdish Dattani	Dr. Ramesh Kulkarni	General Medicine	"Prospective study to observe and analyse the early predictors of severity of Covid19 disease in patients presenting with hypoxia"
10	Dr. Sakshi Jain	Dr. Gouri	Emergency	A prospective observational

Sr. No.	Name Of Principal Investigator	Name Of Guide / Supervisor	Specialty / Department	Title Of Thesis Protocol
		Ranade	Medicine	study to evaluate utility of shock index and lactate level to predict outcome in non traumatic emergency department patients requiring ICU admission.
11	Dr. Bhagwat Sanjana Atul	Dr. Gadhikar Harshal Prabhakar	Gastroenterology	Utility of Metabolic Associated Fatty Liver Disease (MAFLD) Criteria and AST To Platelet Ratio Index (APRI), FIB-4 In Patients Of Non-Alcoholic Fatty Liver Disease (NALFD)
12	Dr. Chinmay Kumbhar	Dr. Rahul Kulkarni	Neurology	To study the pattern of neurological manifestations of HIV in the era of highly Active Anti-Retroviral Therapy
13	Dr Bagade Apurva Anil	Dr Atul Mulay	Nephrology	Correlation of change in office blood pressure with change in 24-hour ambulatory blood pressure in patients with chronic kidney disease
14	Dr. Vrushasen Baburao Mali	Dr. Bhagyashree Shivde	Anaesthesiology	Comparison of efficacy of Phenylephrine, Ephedrine and Mephentermine in treatment of spinal anaesthesia induced hypotension and maintenance of haemodynamics in caesarean section.
15	Dr. Deepak Sethia A	Dr. Sameer Jog	Critical Care Medicine	Outcome in critically ill patients with Severe acidosis (pH < 7) – A Prospective Observational study
16	Dr. Shah Kaushal S	Dr. Dalvi Pradip Balasaheb	Critical Care Medicine	Incidence of Blood Stream Infections in COVID -19 patients with severe Acute Respiratory Distress Syndrome - A retrospective study
17	Dr. Dnyaneshwar Sanjab Cheke	Dr. Satej Janorkar	Cardiology	Assess Incidence of Right Ventricular Dysfunction by Tissue Doppler Imaging in patients with Chronic Kidney Disease with Normal LV systolic function on maintenance hemodialysis
18	Dr Rameshnaga Supreeth	Dr Sachin Sharathchandra Hingmire	Medical Oncology	G8 Scoring for Risk Assessment in Elderly Cancer patients : A Prospective observational Study
19	Dr. Arnab Adak	Dr. Dhananjay Kelkar	Surgical Oncology	A Retrospective study to compare quality of life and Loco-Regional recurrence in

Sr. No.	Name Of Principal Investigator	Name Of Guide / Supervisor	Specialty / Department	Title Of Thesis Protocol
				High Rectal Cancers and Low Rectal Cancers after surgery.
20	Dr. Kale Omkar Vivek	Dr. Mahale Nilesh Purushottam	Critical Care Medicine	"Comparative Study Of Venous To Arterial Carbon Dioxide Partial Pressure Difference With Serum Lactate As Prognostic Marker For Septic Shock."
21	Dr. Remanshi Arora	Dr. Arundhati Kanade	Obstetrics and Gynaecology	An observational study to evaluate the outcome of Screening tests for Down's Syndrome in elderly pregnant women.
22	Dr. Bhupendra Singh	Dr. Pawar Balasaheb	Critical Care Medicine	Outcome of CTPA proven Acute Pulmonary Thrombo-embolism associated with COVID-19 Patients- A Retrospective Observational study.
23	Dr. Satyapal Yadav	Dr Prasad Rajhans	Emergency Medicine	Prospective observational study of lactate clearance in septic shock patients during the first 2 hours in the Emergency Department (ED) to predict 24-hour mortality.
24	Dr. Chaudhari Gajanan Ramesh	Dr. Subodh Shivde	UROLOGY (Genito Urinary surgery)	Outcome of buccal mucosa graft urethroplasty : a detailed analysis of success, morbidity and quality of life.
25	Dr. Keyur Suryakant Patel	Dr. Parimal Kulkarni	Plastic and Reconstructive Surgery	A retroprospective study of patterns of occupational hand Injuries and its outcome in a tertiary care hospital.
26	Dr. Navvaf Umer	Dr. Suneel Godbole	Paediatrics	A Cross Sectional Study of Prevalence of Sleeping Issues in Children with Autism Spectrum Disorders as compared to Normal Children with Typical Development in the Age Group of 2-6 years

DEENANATH MANGESHKAR HOSPITAL AND RESEARCH CENTRE, PUNE, M.S., INDIA

PATRON, SUPPORT and DIRECTOR

Dr. Dhananjay S. Kelkar

ANNUAL REPORT 2021-22 – PREPARED BY

Dr. Vaijayanti V. Pethe

Dr. Shweta A. Chitharanjan

Dr. Amrita P. Prayag

Dr. Deepchand H. Agre

Research Department, 14th Floor, Wing C, Super-speciality building, Deenanath Mangeshkar Hospital and Research Centre, Erandawane, Pune 411004, Maharashtra, India.

(020) - 4915 4456 - 4461

http://www.dmhospital.org/research-aboutus

The pandemic angst and woes

Perpetual Covid in the foreseeable future – Long Covid in a subset of cases – Long term health impacts of Covid and Long Covid - Waning immunity to natural infections and vaccinations – Breakthroughs-re-infections – Global health/ vaccine inequity – high risk of the disease in the unvaccinated /antivaxxers, immunocompromised, elderly and people with co-morbidities – Vaccine trials still underway for kids 5 and under – Need for pan-Coronavirus vaccines - Misinformation/disinformation surrounding the disease and vaccines

	As of March 2021	***As of March 2022***
Covid-19 global cases –	130 million	487 million
Global toll –	2.8 million	6.1 million

The pandemic silver lining

mRNA-based technology in infectious diseases and beyond – Vaccines have saved countless lives.

Vaccination rate : as of March 31, 2022

Global : 58.2% *India : 60%*

Tribute Issue
April 2021 – March 2022

Lata Mangeshkar Medical Foundation's

Deenanath Mangeshkar Hospital and Research Centre, Pune, MS, India

We pay tribute to the music legend – Lata Mangeshkar (1929 – 2022)

Research Department, 14th Floor, Wing C, Super-speciality building, Deenanath Mangeshkar Hospital and Research Centre, Erandawane, Pune 411004, Maharashtra, India.
Phone- (020) - 4915 4456 - 61
http://www.dmhospital.org/research-aboutus